



1 **Original Article**

2 **Efficacy of a Polyethylene Oxide–Sodium Carboxymethylcellulose**
3 **Gel in Prevention of Intrauterine Adhesions After Hysteroscopic**
4 **Surgery**

5 Attilio Di Spiezio Sardo, MD, PhD*, M. Spinelli, MD, S. Bramante, MD, M. Scognamiglio, MD,
6
7
8
9^{Q1} E. Greco, MD, M. Guida, MD, V. Cela, MD, and C. Nappi, MD

10 *From the Department of Gynaecology and Obstetrics, and Pathophysiology of Human Reproduction (Drs. Di Spiezio, Spinelli, Bramante, Scognamiglio,*
11 *Greco, Guida, and Nappi), University of Naples "Federico II," Naples, Italy, and Department of Reproductive Medicine and Child Development (Dr. Cela),*
12 *Division of Obstetrics and Gynecology, University of Pisa, Pisa, Italy.*

13
14 **ABSTRACT** **Study Objectives:** To assess the efficacy of a polyethylene oxide–sodium carboxymethylcellulose gel (Intercoat; Gynecare,
15 division of Ethicon, Inc., Somerville, NJ) in preventing the development of de novo intrauterine adhesions (IUAs) after hys-
16 teroscopic surgery and to rate the patency of the internal uterine ostium at 1-month follow-up diagnostic hysteroscopy.

17 **Design:** Randomized controlled study (Canadian Task Force classification I).

18 **Setting:** University hospital.

19 **Patients:** One hundred ten patients diagnosed during office hysteroscopy as having single or multiple lesions suitable for sur-
20 gical treatment or resistant dysfunctional uterine bleeding requiring endometrial ablation.

21 **Interventions:** Patients were randomized to 2 groups. Group 1 underwent hysteroscopic surgery plus intrauterine application
22 of Intercoat gel, and group 2 underwent hysteroscopic surgery only (control group). Follow-up office hysteroscopy was per-
23 formed at 1 month after surgery to assess the rate and severity of IUA formation and to rate the patency of the internal uterine
24 ostium after the surgical intervention.

25 **Measurements and Main Results:** Compared with the group 2, group 1 demonstrated a significant reduction in the incidence
26 (6% vs 22%; $p < .05$) of de-novo IUAs. Application of the gel seemed to reduce the severity of IUAs, with fewer moderate and
27 severe IUAs at follow-up in group 1 in comparison with group 2 (33% vs 92%). Furthermore, group 1 demonstrated significant
28 improvement in the degree of patency of the internal uterine ostium (41.9% of cases) in comparison with diagnostic office
29 hysteroscopy performed at enrollment ($p < .05$). In contrast, in group 2, worsening of patency of the internal uterine ostium
30 was recorded in 18.2% of cases ($p < .05$).

31 **Conclusions:** Intercoat gel seems to prevent de novo formation of IUAs and to improve the patency of the internal uterine
32 ostium at follow-up hysteroscopy. However, larger studies are needed to confirm these findings. *Journal of Minimally Invasive*
33 *Gynecology* (2011) ■, ■–■ © 2011 AAGL. All rights reserved.

34 **Keywords:** Barrier agent; Cervical patency; hysteroscopic surgery; Intrauterine adhesions; prevention

35 Intrauterine adhesions (IUAs) are fibrous intrauterine
36 bands on opposing walls of the uterus. The primary factors
37 that may trigger IUA formation include curettage after abor-
38 tion or postpartum, when the uterus is more prone to injury;
39

35 infections; prolonged retention of an intrauterine device; and
36 operative hysteroscopy [1–4].

37 Recent developments in technique and technology have
38 encouraged the rapid widespread use of hysteroscopic sur-
39 gery while reducing the need for traditional curettage.
40 Therefore, as the number of operative hysteroscopic proce-
41 dures has increased, the rate of postsurgical IUAs has also
42 become higher, currently representing the major long-term
43 complication of operative hysteroscopy [3,5,6].

44 The frequency of postsurgical IUAs varies according to
45 the indication for surgery, severity of the condition, patient
46 age, and type of surgical procedure [1,7]. Few articles
47 reporting the incidence of postsurgical IUAs (6%; single
48
49

41 The authors have no commercial, proprietary, or financial interest in the
42 products or companies described in this article.

43 Corresponding author: Attilio Di Spiezio Sardo MD, PhD, Department of
44 Gynecology and Obstetrics, and Pathophysiology of Human Reproduction,
45 University of Naples "Federico II," Via Pansini 5, Naples 80131, Italy.
46 E-mail: cdispie@tin.it

47 Submitted February 5, 2011. Accepted for publication April 22, 2011.
48 Available at www.sciencedirect.com and www.jmig.org

49 1553-4650/\$ - see front matter © 2011 AAGL. All rights reserved.
doi:10.1016/j.jmig.2011.04.007

myomectomy, 33%; and multiple myomectomy, 45%) have demonstrated that the complexity of the hysteroscopic surgery is one of the primary determinants of IUA formation metroplasty [1,3,8,9].

Intrauterine adhesions can be classified as *de novo* when they develop at sites that did not have adhesions initially, and as re-formed when they redevelop at sites where adhesiolysis had been previously performed [2]. They can be also classified by the degree of obliteration of the uterine cavity. Over time, several scoring systems have been described to classify the severity of IUAs [8–14]. However, the American Fertility Society classification system is used by most of the gynecologic community [10].

Intrauterine adhesions are important clinically because they may result in infertility, recurrent miscarriage, and irregular cycles with dysmenorrhea and pelvic pain [9–18]. Furthermore, an IUA that either partially or completely obstructs the isthmus or the internal uterine ostium may cause hematometra, severe cramping pelvic pain, and difficulties in accessing the uterine cavity during office hysteroscopy.

Adherence to appropriate hysteroscopic surgical techniques may minimize the risk of postoperative IUAs. General recommendations include preventing trauma to healthy endometrium and myometrium surrounding the lesions to be removed; reducing the use of electrosurgery when possible [19], especially during removal of myomas with extensive intramural involvement [20]; and averting forced cervical manipulation [21].

Several strategies have been developed in an attempt to minimize the risk of postsurgical IUAs [22–24] including administration of pharmacologic agents such as antibiotics [25], gonadotropin-releasing hormone analogues [1], and postoperative conjugated estrogens [26]; use of barrier methods such as a Foley catheter or an intrauterine device [27–29]; and application of gel [3,6]. However, at present, no single method has proved unequivocally effective in preventing postoperative IUAs [21].

Intercoat Absorbable Adhesion Barrier Gel (Gynecare, division of Ethicon, Inc., Somerville, NJ) is a viscoelastic gel formulated for laparoscopic application. It is composed of polyethylene oxide and sodium carboxymethylcellulose stabilized with calcium chloride, and has high tissue adherence and persistence sufficient to prevent adhesion formation [30–32].

The objective of this prospective, randomized, controlled study was to assess the efficacy of Intercoat gel in preventing postsurgical *de novo* adhesions after hysteroscopic surgery and in improving the patency of the internal uterine ostium at 1-month-follow-up hysteroscopy.

Materials and Methods

The protocol of this study was approved by our institutional review board, and the study was performed according to the guidelines of the 1975 Declaration of Helsinki on human experimentation.

All premenopausal women diagnosed at office diagnostic hysteroscopy as having single or multiple lesions suitable for surgical treatment or with resistant dysfunctional uterine bleeding requiring endometrial ablation were invited to participate in the study. Between September 2008 and June 2009, 110 premenopausal women were enrolled in the study. Before enrollment, the objectives of the study were explained clearly to all patients, and written consent was obtained.

Exclusion criteria were body mass index greater than 30, Q_2 menopause (follicle-stimulating hormone concentration >40 mIU/mL and 17β -estradiol <20 pg/mL) or pregnancy (positive beta-human chorionic gonadotropin test results), uterovaginal prolapse, and severe urinary symptoms, malignancy, or other serious concurrent condition (e.g., coagulative disorders, systemic disease, and severe cardiac disease). Preexisting IUAs were considered an exclusion criteria because evaluation of re-formed IUAs was not the focus of the study.

Office diagnostic hysteroscopy was performed using a 5-mm-diameter continuous-flow hysteroscope with oval profile, a 30-degree fore-oblique telescope, and a 5F operating channel (Karl Storz GmbH & Co. KG, Tuttlingen, Germany). Saline solution was used as distention medium (0.9% NaCl), and was administered using an electronic system of irrigation/aspiration (Endomat; Karl Storz GmbH & Co. KG). A stable intrauterine pressure of approximately 40 mm Hg was obtained by setting the flow rate at 220 to 350 mL/min, negative pressure suction at 0.2 bar, and irrigation pressure at 100 mm Hg. No analgesic drugs or anesthesia was administered to the patients.

The type and characteristics of pathologic conditions and the patency of internal uterine ostium (Table 1) were thoroughly recorded on a dedicated form. After diagnostic hysteroscopy, patients were randomized via computer-generated randomization list into group 1 (treatment group: operative hysteroscopy plus intrauterine application of Intercoat gel; $n = 55$) and group 2 (control group: operative hysteroscopy alone; $n = 55$).

Operative hysteroscopy was performed using a rigid 27F resectoscope with a 30-degree fore-oblique telescope with various bipolar loops and a bipolar energy source (Versapoint; Gynecare, division of Ethicon, Inc.). Normal saline solution (0.9% NaCl) was used as the distention medium. The cervical canal was cautiously and progressively dilated using Hegar dilators before introduction of the resectoscope into the uterine cavity. Polyps were treated by positioning the loop behind the base of the pedicle and pushing from back to front. Depending on the size of the lesion being treated, 1 or several passages of the activated loop were necessary. Myomectomy was performed via resection of the free side of the myoma by moving the activated bipolar loop from back to front until normal myometrium was exposed. When the intramural part of the myoma was removed using the bipolar loop, particular care was used to avert any damage to the underlying myometrium. Metroplasty was performed using a modified 0-degree equatorial loop.

Table 1

Classification of patency of internal uterine ostium

Passage	Procedure
Easy	Hysteroscope passes through the cervix without difficulty
Moderately difficult	Slight cervical adhesions are present and are passed over using 1 of the following techniques: Blunt adhesiolysis with tip of hysteroscope Grasping forceps are inserted within fibrous tissue with jaws closed, then gently opened Scope is rotated 90 degrees on the endoscopic camera to align the main axis of the hysteroscope with the axis of the internal uterine ostium
Very difficult	Dense adhesions are present and are passed over using 1 of the following techniques: Scissors are gently inserted in the fibrous tissue, which is cut at 2 or 3 sites 5F bipolar electrodes are used to make 3 or 4 radial incisions at approximately 3-, 6-, 9-, and 12-o'clock positions on the internal uterine ostium

Uterine septae were cut in the midline portion from the proximal part to the uterine fundus until a normal fundus shape was achieved. Endometrial ablation was performed by resecting progressively the posterior, anterior, and lateral uterine walls, preserving the isthmic portion, using a 90-degree bipolar loop. Then the fundus and tubal ostia were resected using a modified 0-degree equatorial loop.

After surgery, group 1 underwent intrauterine application of 10 mL Intercoat gel under hysteroscopic guidance through the inflow channel of the resectoscope while the operator gradually moved the resectoscope from the fundus of the uterus back to the external uterine ostium to apply the gel throughout

the cavity and the cervical canal (Fig.1). The procedure was considered complete when under hysteroscopic visualization the gel seemed to have replaced all of the liquid medium and the cavity appeared completely filled by the gel from the tubal ostia to the external uterine orifice.

In group 2 (control), only hysteroscopic surgery was performed.

Patients in both groups underwent follow-up office hysteroscopy at 1 month after the surgical procedure (during the early proliferative phase of the following menstrual cycle), during which rate and severity were assessed. At 3 months after hysteroscopic surgery, the menstrual pattern was assessed in all patients. Intrauterine adhesions were defined as mild, moderate, or severe according to the American Fertility Society score (Table 2). In both groups, ease of passage through the cervical canal was assessed as previously described (Table I). Instrumentation and settings at follow-up hysteroscopy were the same as those used during hysteroscopy performed at enrollment.

Both the initial and follow-up diagnostic hysteroscopy were performed by the same surgeon (G.M.), who, blinded to patients' randomized allocation, also evaluated the rate and severity of adhesions in each patient. Operative hysteroscopy and application of the Intercoat gel were performed by another surgeon (A.D.S.S.). To prevent any bias related to the surgical treatment, the surgeon was informed of a patient's allocation immediately after surgical removal of the intrauterine lesion or after endometrial ablation.

Statistical Analysis

The primary outcome was measured by the incidence of de novo IUAs. On the basis of data previously published by our group [3,6], the incidence of adhesions at follow-up in patients undergoing hysteroscopic procedures with application of the gel was expected to be 10%, and without the gel to be 28%. These percentages are consistent with the current literature [1,3,6,7], which gives a mean incidence of IUAs of 25% after common resectoscopic procedures (polypectomy,

Fig. 1

The operator gradually moves the resectoscope from the fundus of the uterus back to the external uterine ostium to apply the gel throughout the cavity (A) and the cervical canal (B).

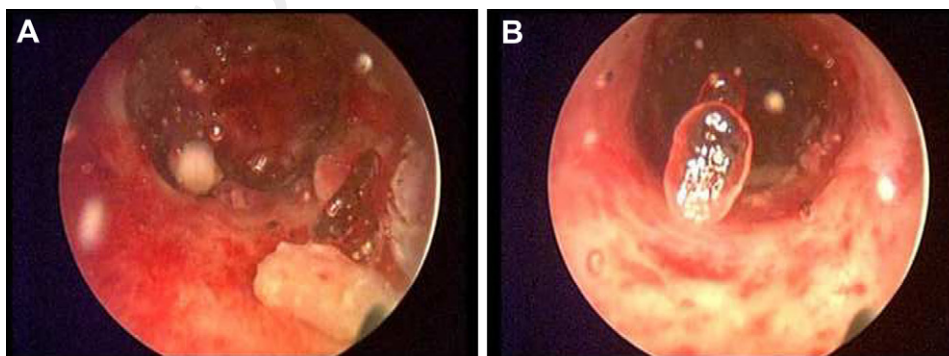


Table 2

Classification of intrauterine adhesions according to AFS guidelines [21]

Variable	Characteristic and AFS Classification		
Extent of cavity involvement	<1/3 1	<1/3 to 2/3 2	>2/3 4
Type of IUAs	Filmy 1	Filmy and dense 2	Dense 4
Menstrual pattern	Normal 0	Hypomenorrhea 2	Amenorrhea 4
Prognostic classification		HSG score ^a	Hysteroscopy score
Stage I, mild	1–4	AF	AF
Stage II, moderate	5–8	AF	AF
Stage III, severe	9–12	AF	AF

AF = additional findings; AFS = American Fertility Society; HSG = hysterosalpingography; IUA = intrauterine adhesion.

^a All adhesions should be considered dense.

myomectomy, and metroplasty) if adjusted by taking into account that the present study was meant to include more adhesiogenic procedures such as endometrial ablation. For the probability of a type 1 statistical error to be less than .05, it was calculated that a sample of 55 patients per group would provide 80% statistical power. Secondary outcome measures included severity of post-surgical IUAs and patency of the internal uterine ostium at 1-month follow-up hysteroscopy. However, no statistical power analysis was attempted for these latter variables.

Statistical analysis was performed using commercially available software (Statistica for Windows; StatSoft, Inc., Tulsa, OK). The intention-to-treat analytical method was used. Data distribution was performed using the Shapiro-Wilks test. Differences in age, weight, and parity, which exhibited a normal distribution, were compared using the *t* test for unpaired data. The χ^2 test was used to compare the rate and severity of IUAs and the degree of patency of the internal uterine ostium between groups before and after the intervention. Statistical significance was considered at $p < .05$.

Results

Between September 2008 and June 2009, 136 patients attending our Office Hysteroscopy Clinic met the inclusion criteria and were invited to participate in the study. Of 26 patients who declined to participate, 8 declined after being explained the study protocol, and 18 were excluded because they were not willing to undergo surgery (Fig. 2). Characteristics of patients enrolled in the study are given in Table 3. At baseline, there were no significant differences in age, weight, uterine size, parity, and clinical symptoms between groups 1 and 2. In addition, there were no significant differences in size and type of lesions between the 2 groups and in the number of patients requiring endometrial ablation (Table 3). All submucous myomas were classified as grade 0, 1, or 2 according to the international classification of uterine myomas [33].

Intention-to-treat was the analysis method used; however, there were no deviations from random allocation. At 1-month

follow-up, a significantly lower rate of post-surgical IUAs was observed in group 1 (3 of 55) compared with group 2 (12 of 55) (6% vs 22%; $p < .05$).

The severity of IUAs was lower in group 1 compared with group 2. In particular, the rate of moderate and severe IUAs was lower in group 1 (1 of 3) compared with group 2 (11 of 12) (33% vs 92%) (Table 4).

Patency of the internal uterine ostium was classified on the basis of difficulty of passage through the cervical canal (i.e., easy, moderately difficult, and difficult) (Fig. 3). At baseline hysteroscopy, in group 1, passage of the hysteroscope through the cervical canal was assessed as easy in 29 patients (53%), moderately difficult in 18 patients (32%), and difficult in 8 patients (15%). At follow-up hysteroscopy, passage was assessed as easy in 44 patients (80%), and moderately difficult in the remaining 11 patients (20%). In group 2, passage of the hysteroscope through the cervical canal was assessed as easy in 33 patients (60%), moderately difficult in 17 patients (31%), and difficult in 5

Fig. 2

Patient enrollment and randomized assignment. In group 1, patients underwent hysteroscopy plus application of Intercoat gel. In group 2, patients underwent hysteroscopy alone (control group).

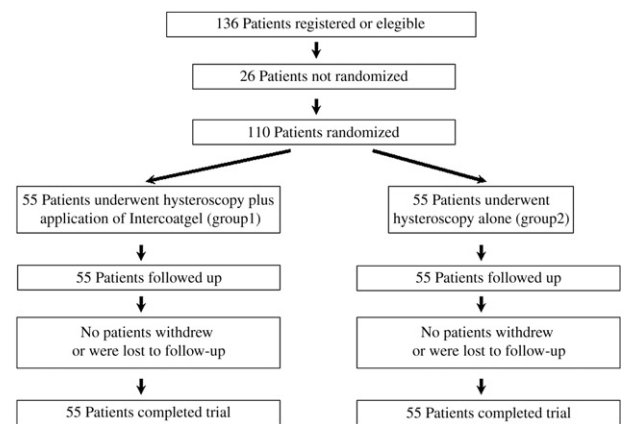


Table 3Characteristics of enrolled patients^{a,b}

Variable	Group 1, ACP Gel (n = 55)	Group 2, Control (n = 55)
Age, yr	37 (3.1)	36 (2.9)
BMI	24.6 (2.8)	24.8 (2.7)
Uterine size at hysterometry, cm	7.4 (1.3)	7.3 (2.4)
Parity	1.5 (0.3)	1.6 (0.2)
Indication for hysteroscopy, No. of patients		
AUB	36	38
Infertility	7	5
AUB and infertility	5	4
Other	7	8
Lesion type, No.		
Polyp	22	20
Myoma	16	15
Grade 0	8	6
Grade 1	4	6
Grade 2	4	3
Lesion size, cm		
Polyp	3.2 (0.3)	3.1 (0.4)
Myoma	2.5 (0.4)	2.7 (0.5)
Septae, No.	6	7
DUB, No. of patients	11	13

AUB = abnormal uterine bleeding; BMI = body mass index; DUB = dysfunctional uterine bleeding; NS = not significant.

^a Unless otherwise indicated, data are given as mean (SD).^b p = NS for all comparisons.

patients (9%). At follow-up hysteroscopy, passage was assessed as easy in 30 patients (55%), moderately difficult in 14 patients (25%), and difficult in 11 patients (20%).

Overall, compared with baseline, at follow-up hysteroscopy, improvement in the degree of patency of the internal uterine ostium was reported in 23 of 55 patients (41.9%) in group 1. Of these, moderately difficult passage in 15 patients and difficult passage in 8 became easier at follow-up hysteroscopy. In the other 31 patients (56%), no modification in patency of the internal uterine ostium occurred. In 1 patient (2.1%), worsening of patency of the internal uterine ostium was recorded (Fig. 3). In contrast, in group 2, worsening of patency of the internal uterine ostium was reported in 10

patients (18.2%). In the other 42 patients (76%), no modification in patency of the internal uterine ostium occurred. In 3 patients (5.8%), improvement in patency of the internal uterine ostium was recorded (Fig. 3). Improvement in patency of the internal uterine ostium at follow-up hysteroscopy was significantly higher in group 1 (23 of 55) than in group 2 (3 of 55) (41.9% vs 5.8%; $p < .05$). In contrast, worsening of patency at follow-up hysteroscopy was significantly higher in group 2 (10 of 55) in comparison with group 1 (1 of 55) (18.2% vs 2.1%; $p < .05$). No adverse gel-related adverse effects were detected in group 1.

Discussion

Intrauterine adhesions were first described at the end of the 19th century by Heinrich Fritsch, who in 1894 reported IUAs in a patient with amenorrhea after postpartum curettage. In 1950, Joseph Asherman published data from the first large series of IUAs.

The most important causes of IUAs are previous trauma to the uterine cavity [34]. With damage to the basilar layer of the endometrium, granulation tissue on either side of the endometrial cavity can fuse, forming tissue bridges [35–37]. Approximately 90% of severe IUAs are related to curettage performed because of complications of pregnancy [34]; however, adhesions can develop in the non-gravid uterus as a result of endometrial injury from procedures such as operative hysteroscopy [1–3]. Similar to the basalis layer of the endometrium, the endocervical mucosa is also susceptible to iatrogenic damage, the inflammatory response causing bridging connecting the anterior and posterior cervical walls. Adhesions that partially or completely obstruct the internal uterine ostium may result in variable narrowing of the cervical canal.

In clinical practice, we have observed worsening of patency of the internal uterine ostium after operative hysteroscopy, probably related to trauma to the cervical tissue during progressive dilation using Hegar probes that necessarily precedes introduction of a standard 27F resectoscope into the uterine cavity. Other factors that influence development of cervical stenosis include postmenopausal status [38,39], nulliparity [40], and cervical surgery [38,41]. Currently, cervical stenosis is a troublesome clinical problem and is the main cause of failure of office hysteroscopy [42,43].

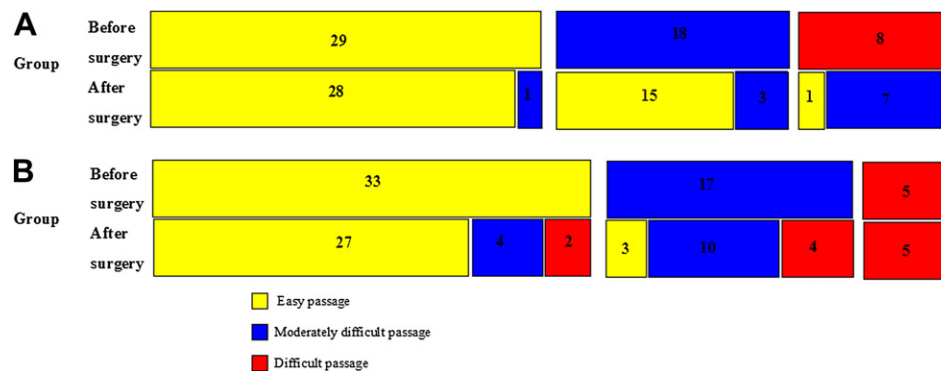Table 4

Severity of post-surgery intrauterine adhesions

Severity	Group 1	Group 2
Mild	2 (1 myomectomy, 1 endometrial ablation)	1 (1 metroplasty)
Moderate	1 (endometrial ablation)	8 (2 myomectomy, 4 endometrial ablation, 2 metroplasty)
Severe	0	3 (1 myomectomy, 2 endometrial ablation)
Total	3	12

Fig. 3

Graphic representation of degree of difficulty in passage of the hysteroscope through the internal uterine ostium (IUO) at baseline and at follow-up hysteroscopy in groups 1 and 2.



Strategies for prevention of post-surgical IUAs include a wide variety of adjuvant pharmacologic agents including antibiotics [25], gonadotropin-releasing hormone analogues [1], and estrogenic [26]. A new category of adhesion prevention methods is barrier systems that maintain opposing uterine walls apart, averting formation of fibrin bridges and subsequent adhesion formation [3,6,34,44]. Such systems include intrauterine insertion of a Foley catheter or an intrauterine device [27-29, 45], as well as synthetic and natural polymer barriers [46-53].

In 2003, Acunzo et al [6] described the introduction of auto-cross-linked hyaluronic acid (ACP) gel into the uterine cavity at the end of the hysteroscopic surgery, demonstrating that the intrauterine application of ACP gel after hysteroscopic adhesiolysis significantly reduces re-formation of postoperative IUAs. In a further randomized controlled study, Guida et al [3] demonstrated that ACP also significantly reduces both the incidence and severity of de novo formation of IUAs after resectoscopic removal of myomas, polyps, and septae.

One of the most recently developed products is the Intercoat absorbable adhesion barrier gel (Gynecare, division of Ethicon, Inc.), a clear single-use flowable gel that is a sterile absorbable combination of polyethylene oxide and sodium carboxymethylcellulose. Manufactured as a thin sheet, it was proved effective in a rabbit laparoscopy model [31], and in human beings, it reduces epidural fibrosis and radiculopathy after lumbar surgery [54,55]. The antiadhesive effect of Intercoat is believed to be a consequence of its barrier effect, keeping the traumatized surfaces separated for a sufficient duration [32].

Currently, few studies in the literature have evaluated the efficacy of Intercoat gel in prevention of adhesions in gynecologic laparoscopic and open surgery [56]. However, to our knowledge, no study has investigated the role of Intercoat gel in preventing post-surgical IUAs and obstruction of the internal uterine ostium. The latter issue seems to be of particular interest because it may result in failure of follow-up office hysteroscopy after resectoscopic surgery.

Our randomized controlled trial demonstrated a significant reduction in de novo IUAs in patients treated with intrauterine application of Intercoat gel after hysteroscopic surgery in comparison with patients treated with hysteroscopic surgery alone. In both groups, the incidence of de novo IUAs was slightly lower than expected. This may be explained by increased surgical experience and use of a modern bipolar resectoscope with lower power settings.

Between the 2 groups, a trend in different severity of adhesions was observed. However, because of the small number of cases included, this trend did not reach statistical significance. Because of the paucity of samples, the rate and severity of adhesions was not assessed within individual pathologic subgroups in the presence or absence of Intercoat gel because of loss of statistical power. However, clinical experience and previous studies report that a higher frequency of postoperative adhesions is frequently observed after endometrial ablation resectoscopic myomectomy and metroplasty but not endometrial polypectomy [20]. Our data are consistent with both the current literature and clinical experience, which report a lower incidence of IUAs after polypectomy compared with other procedures including metroplasty, myomectomy, and endometrial ablation (Table 3).

The present study has demonstrated a significant improvement in the degree of patency of the internal uterine ostium at follow-up hysteroscopy in patients treated with intrauterine application of Intercoat gel after hysteroscopic surgery. In contrast, in the control group, significant worsening of patency was recorded in 18.2% of cases. This positive effect of Intercoat gel may be due to the particular technique used to apply the gel in the uterine cavity: the operator gradually moved the resectoscope from the fundus of the uterus to the external uterine ostium to apply the gel throughout the cervical canal. A potential shortcoming of Intercoat gel may be due to incomplete or patchy application of the gel, leaving some parts of the uterine walls without the protective film.

Previous studies that evaluated the efficacy of another viscoelastic gel to prevent post-surgical IUAs reported that

the gel should be applied in the uterine cavity but not in the cervix [3,19]. The efficacy of our technique has been confirmed by ultrasonographic data that demonstrate that Intercoat gel was able to keep both uterine and cervical walls separated for at least 24 hours (data not shown).

According to our previous protocol, intention to treat was the chosen analytical method, although strictly speaking, the present study was an explanatory investigation rather than a pragmatic trial for effectiveness. No deviation from random allocation and no dropouts occurred, probably because of short interval before follow-up. The choice to schedule follow-up hysteroscopy at only 1 month was made because the adhesiogenic process starts immediately after endometrial injury, and at 2 to 4 weeks after surgery, IUAs can be evaluated at diagnostic hysteroscopy [57]. In addition, early hysteroscopy provides the opportunity to perform adhesiolysis, if needed, when post-surgical IUAs are still thin and soft [57]. Conversely, IUAs discovered at late hysteroscopy are thicker, more organized, and fibrous [57]. This progression of development over time is well documented in the surgical literature [57–59].

Furthermore, early follow-up hysteroscopy may influence the mechanism of adhesiogenesis after hysteroscopic surgery [57]. For this reason, we decided to not schedule patients for a second late hysteroscopy because the rate and severity of IUAs may have been biased by the earlier surgery. The lack of late follow-up hysteroscopy and the small sample size may be a limitation of this study, and more multicenter trials will be needed to confirm our observations.

No adverse effects occurred in group 1. Intercoat gel and other reabsorbable solid or semisolid barriers seem to be safe, which is not surprising because they are based on natural products. In the few available previous trials, no device-related adverse effects have been reported [31,54,55].

Conclusions

Although not definitive, the present data demonstrate that Intercoat gel seems to prevent de novo formation of intrauterine adhesions and also to improve patency of the internal uterine ostium at follow-up hysteroscopy. This new absorbable barrier agent could represent a safe and effective strategy to improve women's health, reducing the need for repeat intervention after hysteroscopic surgery because of postoperative IUA formation and decreasing the failure rate of office hysteroscopy. However, these results need to be confirmed in larger controlled, randomized, multicenter studies.


References

1. Taskin O, Sadik S, Onoglu A, Gokdeniz R, Erturan E, Burak F, Wheeler JM. Role of endometrial suppression on the frequency of intrauterine adhesions after resectoscopic surgery. *J Am Assoc Gynecol Laparosc.* 2000;7:351–354.
2. Diamond MP, Daniell JF, Feste J, Surrey MV, McLaughlin DS, Friedmann S, Vaughn WK, Martin DC. Adhesion reformation and de novo adhesion formation after reproductive pelvic surgery. *Fertil Steril.* 1987;47:864–866.

3. Guida M, Acunzo G, Di Spiezio Sardo A, Bifulco G, Piccoli R, Pellicano M, Cerrota G, Cirillo D, Nappi C. Effectiveness of auto-cross-linked hyaluronic acid gel in the prevention of intrauterine adhesions after hysteroscopic adhesiolysis: a prospective randomized, controlled study. *Hum Reprod.* 2004;19:1461–1464.
4. Al-Inany H. Intrauterine adhesions. *Acta Obstet Gynecol Scand.* 2001;80:986–993.
5. Touboul C, Fernandez H, Deffieux X, Berry R, Frydman R, Gervaise A. Uterine synechiae after bipolar hysteroscopic resection of submucosal myomas in patients with infertility. *Fertil Steril.* 2009;92:1690–1693.
6. Acunzo G, Guida M, Pellicano M, Tommaselli GA, Di Spiezio Sardo A, Bifulco G, Cirillo D, Taylor A, Nappi C. Effectiveness of auto-cross-linked hyaluronic acid gel in the prevention of intrauterine adhesions after hysteroscopic adhesiolysis: a prospective randomized, controlled study. *Hum Reprod.* 2003;18:1918–1921.
7. Liakakos T, Thomakos N, Fine PM, Dervenis C, Young RL. Peritoneal adhesions: etiology, pathophysiology, and clinical significance. *Dig Surg.* 2001;18:260–273.
8. Donnez J, Nisolle M. Hysteroscopic lysis of intrauterine adhesions (Asherman's syndrome). In: Donnez J, editor. *Atlas of Laser Operative Laparoscopy and Hysteroscopy.* London, England: Parthenon Publishers; 1994. p. 305–322.
9. Valle RF, Sciarra JJ. Intrauterine adhesions: hysteroscopic diagnosis, classification, treatment, and reproductive outcome. *Am J Obstet Gynecol.* 1988;158:1459–1470.
10. American Fertility Society. The American Fertility Society classifications of adnexal adhesions, distal tubal occlusion, tubal occlusion secondary to tubal ligation, tubal pregnancies, mullerian anomalies and intrauterine adhesions. *Fertil Steril.* 1988;49:944–955.
11. Asherman JG. Amenorrhea traumatica (atretica). *J Obstet Gynaecol Br Emp.* 1948;55:23–27.
12. Asherman JG. Traumatic intrauterine adhesions. *Br J Obstet Gynaecol.* 1950;57:892–896.
13. Yu D, Wong YM, Cheong Y, Xia E, Li TC. Asherman syndrome: one century later. *Fertil Steril.* 2008;89:759–779.
14. Berman JM. Intrauterine adhesions. *Semin Reprod Med.* 2008;26349–26355.
15. Salzani A, Yela DA, Gabiatti JR, Bedone AJ, Monteiro IM. Prevalence of uterine synechiae after abortion evacuation curettage. *Sao Paulo Med J.* 2007;125:261–264.
16. Deans R, Abbott J. Review of intrauterine adhesions. *J Minim Invasive Gynecol.* 2010;17:555–569.
17. March CM. Asherman's syndrome. *Semin Reprod Med.* 2011;29:83–94.
18. Menzies D. Postoperative adhesions: their treatment and relevance in clinical practice. *Ann R Col Surg.* 1993;75:147–153.
19. Chen FP, Soong YK, Hui YL. Successful treatment of severe uterine synechiae with transcervical resectoscopy combined with laminaria tent. *Hum Reprod.* 1997;12:943–947.
20. Di Spiezio Sardo A, Mazzon I, Bramante S, Bettocchi S, Bifulco G, Guida M, Nappi C. Hysteroscopic myomectomy: a comprehensive review of surgical techniques. *Hum Reprod Update.* 2008;14:101–119.
21. Nappi C, Di Spiezio Sardo A, Greco E, Guida M, Bettocchi S, Bifulco G. Prevention of adhesions in gynaecological endoscopy [published online ahead of print April 23, 2007]. *Hum Reprod Update.* 2007;13:379–394.
22. Risberg B. Adhesions: preventive strategies. *Eur J Surg Suppl.* 1997;577:32–39.
23. Farquhar C, Vandekerckhove P, Watson A, Vail A, Wiseman D. Barrier agents for preventing adhesions after surgery for subfertility. *Cochrane Database Syst Rev.* 2002;(2):CD000475.
24. Watson A, Vandekerckhove P, Lilford R. Liquid and fluid agents for preventing adhesions after surgery for infertility. *Cochrane Database Syst Rev.* 2000;(2):CD001298.
25. Shenker JG. Etiology of and therapeutic approach to synechiae uteri. *Eur J Obstet Gynecol Reprod Biol.* 1996;65:109–113.

- 741 26. Roge P, D'Ercole C, Cravello L, Boublil L, Blanc B. Hysteroscopic
742 management of uterine synechiae: a series of 102 observations. *Eur*
743 *J Obstet Gynecol Reprod Biol.* 1996;65:189–193. 797
- 744 27. Comninos AC, Zourlas PA. Treatment of uterine adhesions (Asher-
745 man's syndrome). *Am J Obstet Gynecol.* 1969;105:862–865. 798
- 746 28. Pabuccu R, Atay V, Orhon E, Urman B, Ergun A. Hysteroscopic
747 treatment of intrauterine adhesions is safe and effective in the res-
748 toration of normal menstruation and fertility. *Fertil Steril.* 1997;68:
749 1141–1143. 799
- 750 29. Orhue AAE, Aziken ME, Igbefoh JO. A comparison of two adjunctive
751 treatments for intrauterine adhesions following lysis. *Int J Gynecol Ob-*
752 *stet.* 2003;82:49–56. 800
- 753 30. Schonman R, Corona R, Bastidas A, De Cicco C, Mailova K,
754 Koninckx PR. Intercoat gel (Oxiplex): efficacy, safety, and tissue re-
755 sponse in a laparoscopic mouse model. *J Minim Invasive Gynecol.*
756 2009;16:188–194. 801
- 757 31. Rodgers KE, Schwartz HE, Roda N, Thornton M, Kobak W,
758 diZerega GS. Effect of Oxiplex* films (PEO/CMC) on adhesion forma-
759 tion and reformation in rabbit models and on peritoneal infection in a rat
760 model. *Fertil Steril.* 2000;73:831–838. 802
- 761 32. Lunderoff P, Donnez J, Korell M, Audebert AJ, Block K, diZerega GS.
762 Clinical evaluation of a viscoelastic gel for reduction of adhesions fol-
763 lowing gynecological surgery by laparoscopy in Europe. *Hum Reprod.*
764 2005;20:514–520. 803
- 765 33. Wamsteker K, Emanuel MH, de Kruif JH. Transcervical hysteroscopic
766 resection of submucous fibroids for abnormal uterine bleeding: results
767 regarding the degree of intramural extension. *Obstet Gynecol.* 1993;82:
768 736–740. 804
- 769 34. De Iaco PA, Muzzupapa G, Bovicelli A, Marconi S, Bitti SR,
770 Sansovini M, Bovicelli L. Hyaluronan derivative gel (hyalobarrier
771 gel) in intrauterine adhesion (IUA) prevention after operative hystero-
772 scopy. *Ellipse.* 2003;19:15–18. 805
- 773 35. Hellebrekers BW, Trimbos-Kemper TC, Trimbos JB, Emeis JJ,
774 Kooistra T. Use of fibrinolytic agents in the prevention of postoperative
775 adhesion formation. *Fertil Steril.* 2000;74:203–212. 806
- 776 36. Robinson J, Swedarsky Colimon LM, Isaacson KB. Postoperative adhe-
777 siolysis therapy for intrauterine adhesions (Asherman's syndrome)
778 [published online ahead of print June 20, 2008]. *Fertil Steril.* 2008;
779 90:409–414. 807
- 780 37. Panayotidis C, Weyers S, Bosteels J, van Herendael B. Intrauterine ad-
781 hesions (IUA): has there been progress in understanding and treatment
782 over the last 20 years? *Gynecol Surg.* 2009;6:197–211. 808
- 783 38. Suh-Burgmann E, Whall-Strojwas D, Chang Y, Hundley D,
784 Goodman A. Risk factors for cervical stenosis after loop electrocautery
785 excision procedure. *Obstet Gynecol.* 2000;96:657–660. 809
- 786 39. Bettocchi S, Pansini N, Porreca MR, Selvaggi L. Anatomic impedi-
787 ments to the performance of hysteroscopy. *J Am Assoc Gynecol Lapa-*
788 *rosc.* 1996;3(4 suppl):S4. 810
- 789 40. Litta P, Bonora M, Pozzan C, Mrlin F, Sacco G, Fracas M,
790 Capobianco G, Dessole S. Carbon dioxide versus normal saline in out-
791 patient hysteroscopy. *Hum Reprod.* 2003;18:2446–2449. 811
- 792 41. Baldauf JJ, Dreyfus M, Ritter J, Meyer P, Philippe E. Risk of cervical
793 stenosis after large loop excision or laser conization. *Obstet Gynecol.*
794 1996;88:933–938. 812
- 795 42. Cicinelli E, Parisi C, Galantino P, Pinto V, Barba B, Schonauer S.
796 Reliability, feasibility, and safety of minihysteroscopy with a vagino-
797 scopic approach: experience with 6,000 cases. *Fertil Steril.* 2003;80:
798 199–202. 813
- 799 43. De Angelis Carlo, Perrone G, Santoro G, Nofroni I, Zichella L. Sup-
800 pression of pelvic pain during hysteroscopy with a transcuteaneous elec-
801 trical nerve stimulation device. *Fertil Steril.* 2003;79:1422–1427. 814
- 802 44. Abbott J, Thomson A, Vancaille T. SprayGel following surgery for
803 Asherman's syndrome may improve pregnancy outcome. *J Obstet Gyn-*
804 *naecol.* 2004;24:710–711. 815
- 805 45. Thomson AJ, Abbott JA, Deans R, Kingston A, Vancaille TG. The
806 management of intrauterine synechiae. *Curr Opin Obstet Gynecol.*
807 2009;21:335–341. 816
- 808 46. DeWilde RL, Trew G, on behalf of the Expert Adhesions Working Party
809 of the European Society of Gynaecological Endoscopy (ESGE). Post-
810 operative abdominal adhesions and their prevention in gynecological
811 surgery. Expert consensus position. Part 2: steps to reduce adhesions.
812 *Gynecol Surg.* 2007;4:243–253. 817
- 813 47. Diamond MP, Seprafilm Adhesion Study Group. Reduction of adhe-
814 sions after uterine myomectomy by Seprafilm membrane (HAL-F):
815 a blinded, prospective, randomized, multicenter clinical study. *Fertil*
816 *Steril.* 1996;66:904. 818
- 817 48. Brown CB, Luciano AA, Martin D. Adept (icodextrin 4% solution) re-
818 duces adhesions after laparoscopic surgery for adhesiolysis: a double-
819 blind, randomized, controlled study. *Fertil Steril.* 2007;88:1413. 819
- 820 49. Dunn R, Lyman MD, Edelman PG. Evaluation of the SprayGel adhe-
821 sion barrier in the rat cecum abrasion and rabbit uterine horn adhesion
822 models. *Fertil Steril.* 2001;75:411. 820
- 823 50. Frey C, Chanelles O, Poncelet C. How to prevent postoperative intra-
824 uterine adhesions? *Gynecol Obstet Fertil.* 2010;38:550–552. 821
- 825 51. Revaux A, Ducarme G, Luton D. Prevention of intrauterine adhesions
826 after hysteroscopic surgery. *Gynecol Obstet Fertil.* 2008;36:311–317. 822
- 827 52. Ducarme G, Davitian C, Zarrouk S, Uzan M, Poncelet C. Interest of
828 auto-cross-linked hyaluronic acid gel in the prevention of intrauterine
829 adhesions after hysteroscopic surgery: a case-control study. *J Gynecol*
830 *Obstet Biol Reprod.* 2006;35:691–695. 823
- 831 53. Tsapanos VS, Stathopoulou LP, Papathanassopoulou VS, Tzingounis VA.
832 The role of Seprafilm bioresorbable membrane in the prevention and ther-
833 apy of endometrial synechiae. *J Biomed Mater Res.* 2002;63:10–14. 827
- 834 54. Rodgers KE, Robertson JT, Espinoza T. Reduction of epidural fibrosis
835 in lumbar surgery with Oxiplex adhesion barriers of carboxymethylcel-
836 lulose and polyethylene oxide. *Spine J.* 2003;3:277–283. 828
- 837 55. Kim KD, Wang JC, Robertson DP. Reduction of radiculopathy and pain
838 with Oxiplex/SP gel after laminectomy, laminotomy, and discectomy:
839 a pilot clinical study. *Spine.* 2003;28:1080–1087. 830
- 840 56. Young P, Johns C, Templeman C, Witz C, Webster B, Ferland R,
841 Diamond MP, Block K, diZerega G. Reduction of postoperative adhe-
842 sions after laparoscopic gynecological surgery with Oxiplex/AP gel:
843 a pilot study. *Fertil Steril.* 2005;84:1450. 835
- 844 57. Shokeir TA, Fawzy M, Tatongy M. The nature of intrauterine adhesions
845 following reproductive hysteroscopic surgery as determined by early
846 and late follow-up hysteroscopy: clinical implications. *Arch Gynecol*
847 *Obstet.* 2008;277:423–427. 839
- 848 58. Bradley JM, Michael LB, Montz FJ. Adhesions after extensive gynecolo-
849 gic surgery: clinical significance, etiology, and prevention. *Am J Ob-*
850 *stet Gynecol.* 1994;170:1396–1403. 841
- 851 59. Chapman R, Chapman K. The value of two stage laser treatment for se-
852 vere Asherman's syndrome. *Br J Obstet Gynecol.* 1996;103:1256–1258. 842

AUTHOR QUERY FORM

 ELSEVIER	Journal: JMIG Article Number: 1676	Please e-mail or fax your responses and any corrections to: E-mail: b.arnold@Elsevier.com Fax: 215-239-3388
--	---	---

Dear Author,

Please check your proof carefully and mark all corrections at the appropriate place in the proof (e.g., by using on-screen annotation in the PDF file) or compile them in a separate list. To ensure fast publication of your paper please return your corrections within 48 hours.

For correction or revision of any artwork, please consult <http://www.elsevier.com/artworkinstructions>.

Any queries or remarks that have arisen during the processing of your manuscript are listed below and highlighted by flags in the proof.

Location in article	Query / Remark: Click on the Q link to find the query's location in text Please insert your reply or correction at the corresponding line in the proof
Q1	Please provide first names for all authors. Also, check to ensure that all author names, academic credentials, and affiliations are correct as they appear.
Q2	Because BMI is an index, units are not necessary.
Q3	M.G. meant here (i.e., Dr. Guido)?
Q4	Note that original Fig. 3 is now Table 4. Consequently, original Fig. 4 is now Fig. 3. Please check carefully throughout.
Q5	Please verify all data in reference 23 (Farquhar et al).
Q6	Centimeters correct here?

Thank you for your assistance.