

## TECHNIQUE

## A Novel Method of Screw Placement for Extremely Small Thoracic Pedicles in Scoliosis

Choon Sung Lee, MD, PhD,\* Soo-An Park, MD, PhD,† Chang Ju Hwang, MD, PhD\* Dong-Joon Kim, MD,\*  
Won-Jae Lee, MD,\* Yung-Tae Kim, MD, PhD,\* Mi Young Lee, RN,\* So Jung Yoon, RN,\* and  
Dong-Ho Lee, MD, PhD,\*

**Study Design.** A retrospective clinical study.

**Objective.** To introduce a novel method of pedicle screw placement for extremely small thoracic pedicles in scoliosis and evaluate the safety and accuracy of the method.

**Summary of Background Data.** Few studies have provided technical guidelines for screw placement in patients with extremely small thoracic pedicles in scoliosis.

**Methods.** In a severely rotated scoliotic spine, thoracic pedicle screw placement is challenging, and particularly more so for extremely small pedicles with a diameter less than 2 mm. The authors introduced a novel method of screw placement for these small pedicles: "medial margin targeting method."

The C-arm fluoroscope is rotated until a true PA image of the rotated vertebral body is acquired and both pedicle shadows are symmetrically visualized en face. In extremely small pedicles, pedicle shadows appear as long, slender ellipses or lines. An imaginary pedicle outline is presumed with the elliptical or linear shadows being the medial margin of the pedicle. The entry point of a screw can be made at the 10-o'clock or 2-o'clock position on the presumed pedicle outline, and the screw can be safely inserted targeting the presumed medial margin with caution not to penetrate the medial cortex using the guidance of a true PA image. This is a kind of extrapedicular screw placement method.

The safety and accuracy of this method were evaluated in 97 patients with scoliosis who had undergone posterior correction and instrumentation using postoperative computed tomography scans. A total of 1634 pedicle screws were inserted into thoracic pedicles, 128 of them (7.8%) being extremely small pedicles with a diameter less than 2 mm.

**Results.** Among 128 extremely small thoracic pedicles with a diameter less than 2 mm, one screw (0.8%) violated the medial cortex and 22 screws (17.6%) violated the anterior cortex of the vertebral body. No screws violated the lateral cortex of the pedicle-rib unit. There were no complications associated with screw misplacement.

**Conclusion.** In scoliosis patients with extremely small thoracic pedicles, our pedicle screw placement method targeting the presumed medial margin in a true PA C-arm image allows easy application with accuracy and safety, which would not possible by any other method described so far.

**Key words:** extremely small pedicle, scoliosis, pedicle screw placement, medial margin targeting method, posteroanterior C-arm rotation method. **Spine 2011;36:E1112–E1116**

Various methods of pedicle screw placement have been reported, including the intraoperative biplanar radiograph method,<sup>1</sup> the freehand technique,<sup>2</sup> and the image-guided navigation method.<sup>3,4</sup> Although each method has its respective advantages and disadvantages, none guarantees safety and accuracy for extremely small pedicles in severely deformed and rotated spines, and none is easily performed by surgeons with little experience.

In a severely rotated scoliotic spine, thoracic pedicle screw placement is challenging, and particularly more so for extremely small pedicles with a diameter less than 2 mm. We introduced a novel method of screw placement for these small pedicles. It is based on the posteroanterior (PA) C-arm rotation method for pedicle screw insertion reported by the authors in 2007.<sup>5</sup> This practical, simple and safe pedicle screw placement method for scoliosis allows en face visualization of both pedicles by rotating the C-arm fluoroscope to compensate for the rotational deformity. Another great advantage of this method is that it can be evolved and applied to extremely small thoracic pedicles without much difficulty, overcoming the limitations of other previously reported methods.

The purpose of this study is to describe a novel method of pedicle screw placement for extremely small thoracic pedicles in patients with scoliosis, and to evaluate the clinical safety and accuracy of this method by analyzing screw positions in thoracic pedicles with a diameter less than 2 mm using postoperative computed tomography (CT).

From the \*Scoliosis Center, Asan Medical Center, University of Ulsan College of Medicine, Seoul, Korea; and †Spine Center, Seoul St. Mary's Hospital, Seoul, Korea.

Acknowledgment date: April 7, 2010. Revision date: September 29, 2010. Acceptance date: October 1, 2010.

The manuscript submitted does not contain information about medical device(s)/drug(s).

No funds were received in support of this work. No benefits in any form have been or will be received from a commercial party related directly or indirectly to the subject of this article.

Address correspondence and reprint requests to Chang Ju Hwang, MD, Scoliosis Center, Asan Medical Center, University of Ulsan College of Medicine, 86 Asanbyeongwon-gil, Songpa-gu, Seoul 138-736, Korea; E-mail: baski47@gmail.com

DOI: 10.1097/BRS.0b013e3181f1ee2

E1112 www.spinejournal.com

Copyright © 2011 Lippincott Williams & Wilkins. Unauthorized reproduction of this article is prohibited.

July 2011

## MATERIALS AND METHODS

### Patients

The study involved 97 consecutive patients with scoliosis who had undergone posterior deformity correction and instrumentation using pedicle screw fixation from March 2008 to February 2009. Patient medical records were retrospectively reviewed to obtain demographic data and details regarding screw-related complications. The etiologic diagnoses were idiopathic scoliosis (64 patients), congenital scoliosis (11 patients), neuromuscular scoliosis (9 patients), scoliosis associated with various syndromes (4 patients), and others (8 patients). Degenerative scoliosis patients were excluded from the study. All surgeries were carried out by the first author (C.S.L.). There were 69 female and 28 male patients with a mean age of 15.9 years at the time of surgical treatment. All cases were monitored using somatosensory-evoked potential and motor-evoked potential during surgery.

### Preoperative Evaluation

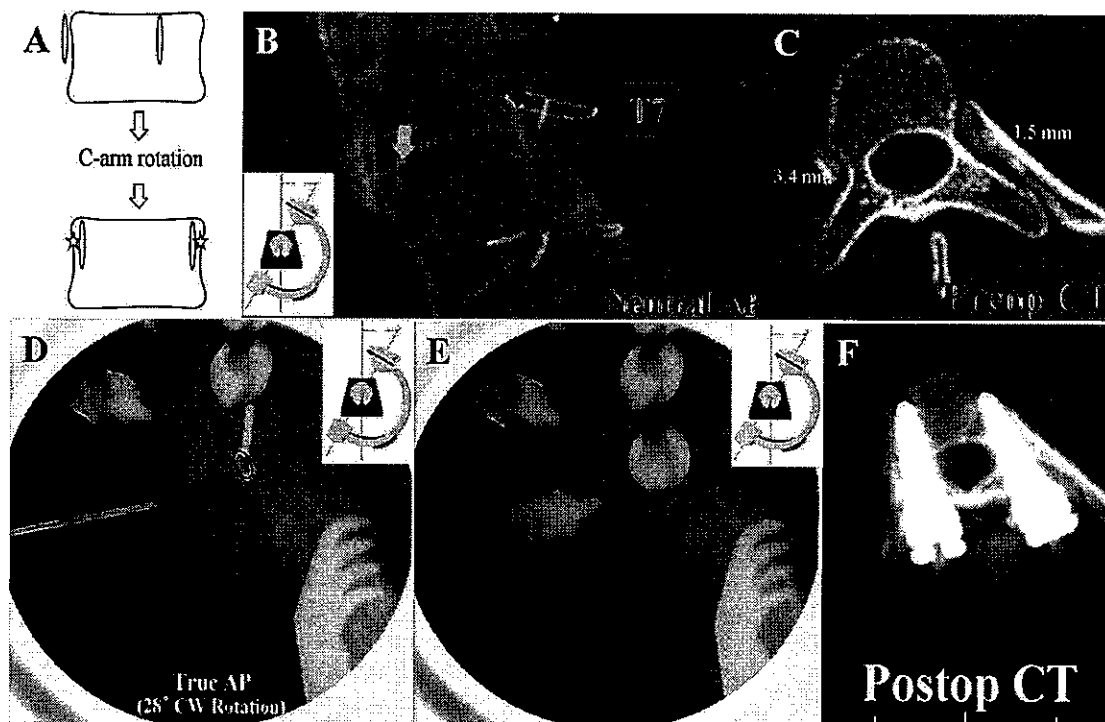
The dimensions of every screw were determined before surgery based on measurements of pedicle morphometry in CT scans. CT images were reconstructed using Advantage Workstation (version 4.4, GE Healthcare, Waukesha, WI) to visualize the centers of both pedicles in one axial plane view. The narrowest transverse diameter of a pedicle between the outer

cortical margins was measured for each thoracic pedicle on the reconstructed axial CT image. Screw diameter was determined according to the narrowest pedicle diameter, and screw length was determined according to the tentative trajectory. An “extremely small pedicle” was defined as a pedicle with a transverse diameter less than 2 mm.

### Surgical Technique

After posterior exposure of the spine, C-arm fluoroscope is positioned at the target vertebra to obtain a PA image. The C-arm is gradually rotated until a true PA view of the rotated vertebral body is acquired and both pedicles are symmetrically visualized en face (Figure 1A). The angle of C-arm rotation requires adjustment at each vertebral level, with the largest rotation usually required for the apical vertebra. Once the symmetrical pedicle shadows are obtained, the C-arm is rotated in a sagittal plane to create a tangential view of both endplates.

On the basis of the round pedicle outline on the C-arm image, the entry points are determined at 10-o'clock and 2-o'clock positions on the left and right pedicles, respectively. However, for extremely small pedicles, pedicle shadows appear as long and slender ellipses or lines (Figure 1B, C). In such cases, an imaginary pedicle outline is presumed with the elliptical or linear shadows being the medial margin of the pedicle. Thus, the entry point of a screw can be made at



**Figure 1.** The medial margin targeting method. A, The C-arm is gradually rotated until a true PA image of the rotated vertebral body is acquired and both pedicles are symmetrically visualized en face. B, For extremely small pedicles, pedicle shadows appear as long and slender ellipses or lines (right pedicle). C, Preoperative axial CT image. Right pedicle diameter is less than 2 mm. D, An imaginary pedicle outline is presumed with the elliptical or linear shadow (arrow) being the medial margin of the pedicle. The entry point of a screw is made at 2-o'clock position in the presumed pedicle outline. E, A pedicle screw is targeted toward the medial margin, but care is taken not to penetrate the medial cortex. F, Postoperative axial CT image. Right pedicle screw was safely purchased between the medial pedicle cortex and the lateral cortex of the corresponding pedicle-rib unit.

**TABLE 1** Comparison of the Proportion of Extremely Small Pedicles with a Diameter Less Than 2 mm Between Concave and Convex Sides, Upper, and Lower Thoracic Regions, and Apical and Nonapical Regions

	≤2 mm (N%)	>2 mm (N%)	Total (N)	P
Total	128 (7.8)	1506 (92.2)	1634	NA
Concave side	77 (9.4)	738 (90.6)	815	<0.001
Convex side	26 (3.2)	793 (96.8)	819	
Upper thoracic	73 (13.1)	484 (86.9)	557	0.07
Lower thoracic	55 (5.1)	1022 (94.9)	1077	
Apical	47 (7.5)	585 (92.5)	632	<0.001
Nonapical	55 (5.5)	967 (94.5)	1002	

*N, numbers; NA, not applicable.*

10-o'clock or 2-o'clock positions on the presumed pedicle outline (Figure 1D). As the screws are inserted with both pedicle shadows symmetrically aligned, the PA image provides information about the direction of the screws in axial and sagittal planes. The pedicle screw is targeted toward the medial margin, but care is taken not to penetrate the medial cortex, using the guidance of a true PA image if necessary: "medial margin targeting method" (Figure 1E). This technique is highly feasible for extremely small thoracic pedicles since a screw can be safely anchored between the medial pedicle cortex and the lateral cortex of the corresponding pedicle-rib unit, especially in severely rotated spines (Figure 1F).

The direction of a screw in axial and sagittal planes is adjusted according to the inclination of the C-arm because C-arm fluoroscopy has been rotated to make a true PA image. Sagittal C-arm images are not taken. The sagittal direction of the screw can also be adjusted depending on the direction of the pedicle (as viewed on simple lateral radiographs taken with the patient on a table) and the gross sagittal curvature of the exposed laminae.

### Postoperative Evaluation

A CT scan was performed for every patient, 2 weeks after surgery to evaluate screw position using the same reconstruction technique as for the preoperative CT scan. To evaluate screw placement accuracy, CT scans were examined to determine whether the long axis of a screw penetrated the medial cortex

of the pedicle, or the lateral cortex of the pedicle-rib unit, and whether the screw tip penetrated the anterior cortex of the vertebral body. If the axis of a screw was outside the medial cortex of the pedicle wall or the lateral cortex of the rib-pedicle unit, it was defined as medial or lateral violation.<sup>6</sup> If the tip of a screw penetrated the anterior cortex of the vertebral body, it was defined as anterior violation. Screw placement was assessed by three independent spine surgeons blinded to all clinical information. If an assessment differed between those surgeons, the position was taken to be that indicated by at least two of the assessors.

### Statistical Analysis

Chi-square tests were used to compare the proportion of extremely small pedicles with a diameter less than 2 mm within instrumented segments between concave and convex sides, upper (T1–T6) and lower (T7–T12) thoracic regions, and apical (apical vertebra plus its one proximal and one distal vertebrae) and nonapical regions. The proportion of pedicles with a diameter less than 3 mm to total pedicles was also calculated. Chi-square tests were also used to compare screw placement accuracy between pedicles of less than 2 mm diameter and pedicles of greater than 2 mm diameter. All statistical tests were performed using SPSS 13.0 for Windows (SPSS Inc., Chicago, IL).

### RESULTS

A total of 1634 thoracic pedicle screws were inserted in 97 patients. All pedicles within the intended fusion range were instrumented with pedicle screws in both convex and concave sides, except some cases in which crowding of the screw heads made every-level screw placement impossible. There were 815 screws on the concave side, and 819 screws on the convex side. The overall percentage of extremely small thoracic pedicles was 7.8% (128 pedicles), and the percentage of small pedicles with a diameter less than 3 mm was 23.1% (377 pedicles).

Extremely small thoracic pedicles with a diameter less than 2 mm were more prevalent in the concave (9.4%) than the

**TABLE 2** Accuracy of Screw Placement

	≤2 mm (N%)	>2 mm (N%)	Total (N%)	P
Medial violation	0.8 (1)	0.3 (5)	0.4 (6)	0.379
Lateral violation	0 (0)	0 (0)	0 (0)	NA
Anterior violation	17.2 (22)	7.1 (107)	7.9 (129)	<0.001

*N, numbers; NA, not applicable.*

convex (3.2%) side ( $P < 0.001$ ), and were also more common in the upper thoracic (13.1%) than the lower thoracic (5.1%) region ( $P < 0.001$ ). Extremely small thoracic pedicles were equally distributed between the apical (7.5%) and nonapical (5.5%) regions ( $P = 0.07$ ).

There were one medial violation (0.8%) in extremely small pedicle group (diameter  $\leq 2$  mm), and five medial violations (0.3%) in larger pedicle group (diameter  $> 2$  mm). This difference was not statistically significant ( $P = 0.379$ ). No lateral violations were observed in either group. Anterior violations were more common in the extremely small pedicle group (17.6%) than in the larger pedicle group (7.1%;  $P < 0.001$ ).

Misplaced screws did not cause any associated complications, and there was no evidence of vital organ injury in postoperative CT scans. There were no abnormalities during intraoperative neurophysiologic monitoring. One patient with severe congenital scoliosis who underwent posterior fusion from T1 to L2 with hemivertebra resection developed temporary Horner syndrome after surgery.

## DISCUSSION

Optimal pedicle screw placement is imperative to minimize screw-related complications and maximize deformity correction in surgical treatment of scoliosis. However, extremely small pedicles prevent visualization of round pedicle shadows, even in true PA images. It is challenging to place screws into such pedicles, which also have a highly variable and complex three-dimensional orientation. Although several techniques have been developed to aid surgeons in pedicle screw placement,<sup>1-4,7-10</sup> none has obtained universal acceptance, and none can guarantee safety and accuracy, especially for extremely small pedicles.

Small pedicles are often encountered in scoliosis surgery. In this study, the proportion of extremely small pedicles was 7.8%. Furthermore, there were 377 pedicles (23.1%) with a diameter less than 3 mm. Most spine surgeons will have difficulty in placing screws if a pedicle diameter is only 3 mm. Such a high incidence of relatively small pedicles requires the development of a novel pedicle screw placement technique other than the existing ones that can guarantee safety and accuracy. Therefore, the authors developed the "medial margin targeting method," described earlier, which is evolved from the PA C-arm rotation method.<sup>5</sup>

The biplanar radiograph technique described by Suk *et al*<sup>1</sup> involves insertion of a guide pin at the presumed pedicle entry point, after which PA and lateral intraoperative radiographs are taken to determine the ideal pedicle entry point and trajectory. However, less-experienced spine surgeons would have difficulty achieving accurate screw placement with this method. It depends greatly on the subjective "feeling" of the surgeon's hand, and has the disadvantages of poor objectivity and standardization. Moreover, the method would be even more inaccurate in cases of severely rotated spinal deformities with extremely small pedicles because visualization of pedicle shadows in simple radiographs becomes almost impossible. Suk *et al*<sup>1</sup> have reported a high margin of safety with a

1.5% malposition rate, but most of the screw positions were evaluated using simple radiographs.

Kim *et al*<sup>2</sup> introduced the "free hand technique" using anatomic landmarks and gearshift probing to avoid the use of any additional methods for insertion of pedicle screws. Although Lehman *et al*<sup>11</sup> reported fairly good results with an overall accuracy of 89.5% in pediatric deformed spine patients (1023 pedicle screws), there have been no reports on its safety and accuracy in cases with extremely small pedicles. Because the technique is highly dependent on the experience and expertise of the surgeon, it can be associated with a relatively high risk, especially in severely rotated and deformed spines with extremely small pedicles, even if it can be safe in normal spine or mild spinal deformity. As indicated by Kim *et al*<sup>2</sup> in the first description of this technique, a pedicle "blush" may not be visualized in small pedicles during gearshift probing after cortical burring of the starting point because of very limited intrapedicular cancellous bone. Hence, in such cases, the technique would not be feasible for safe pedicle screw placement. Lehman *et al*<sup>11</sup> reported there had been several instances of cerebrospinal fluid emanating from the initial pedicle tract during the preparation of the screw holes, leading to abandonment of those screw sites. In contrast, using this method we did not experience any cerebrospinal fluid leakage associated with screw insertion, because it prevents perforation of the medial margin of an extremely small pedicle under the fluoroscopic guidance.

Since Dvorak *et al*<sup>7</sup> developed an extrapedicular thoracic pedicle screw fixation technique as an alternative to conventional intrapedicular screw placement to overcome complications associated with screw misplacement and iatrogenic fracture of pedicles, a number of biomechanical and cadaveric studies have examined its feasibility.<sup>8-10</sup> However, no report has described the technical details and clinical results of extrapedicular screw insertion. Our medial margin targeting method is a type of extrapedicular screw insertion technique for extremely small pedicles, and to our knowledge this is the first technical and clinical report on this technique. Although a few biomechanical studies reported that extrapedicular screws provided slightly inferior pullout strength to intrapedicular screws,<sup>8,9</sup> the extrapedicular technique is undoubtedly an invaluable alternative when standard pedicle screw placement is not possible owing to an extremely small pedicle size.

In this study, there were a negligible number of medial violations in the extremely small pedicle group (1 screw, 0.8%) as well as the larger pedicle group (5 screws, 0.3%). This reflects the high margin of safety and accuracy of the medial margin targeting method compared with other techniques. Anterior violations were found to be relatively common, especially in the extremely small pedicle group. This may indicate that the screw trajectory tended to be less convergent than planned to avoid penetration of the medial pedicular cortex during screw placement. Therefore, for extremely small pedicles we recommend the use of slightly shorter screws than were before surgery estimated, considering divergence tendency of the screws to avoid medial violation.

## CONCLUSION

Small pedicles are often encountered in scoliosis surgery. Previously reported screw placement methods have some limitations in severely rotated spine with extremely small pedicles. Our pedicle screw placement method targeting presumed medial margin in a true PA C-arm image (medial margin targeting method) seems to be accurate, safe, and practical for screw placement in extremely small pedicles. This method may be a unique and invaluable option when less-experienced spine surgeons try to insert screws into extremely small pedicles in patients with scoliosis.

### ➤ Key Points

- ❑ The overall percentage of extremely small thoracic pedicles with a diameter less than 2 mm was 7.8%, and the percentage of small pedicles with a diameter less than 3 mm was 23.1%.
- ❑ Pedicle screws were placed in extremely small pedicles by rotating the C-arm fluoroscope to obtain a true PA image and targeting the presumed medial margin of an imaginary pedicle outline.
- ❑ Our pedicle screw placement method targeting the presumed medial margin in a true PA C-arm image (medial margin targeting method) is accurate, safe, and practical even in a severely rotated scoliotic spine with extremely small thoracic pedicles.

## References

1. Suk SI, Kim WJ, Lee SM, et al. Thoracic pedicle screw fixation in spinal deformities: are they really safe? *Spine* 2001;26:2049-57.
2. Kim YJ, Lenke LG, Bridwell KH, et al. Free hand pedicle screw placement in the thoracic spine: is it safe? *Spine* 2004;29:333-42.
3. Youkellis AS, Quint DJ, McGillicuddy JE, et al. Stereotactic navigation for placement of pedicle screws in the thoracic spine. *Neurosurgery* 2001;48:771-8.
4. Foley KT, Simon DA, Rampersaud YR. Virtual fluoroscopy: computer-assisted fluoroscopic navigation. *Spine* 2001;48:771-8.
5. Lee CS, Kim MJ, Ahn YJ, et al. Thoracic pedicle screw insertion in scoliosis using posteroanterior C-arm rotation method. *J Spinal Disord Tech* 2007;20:66-71.
6. Kim YJ, Lenke LG, Cheh G, et al. Evaluation of pedicle screw placement in the deformed spine using intraoperative plain radiographs: a comparison with computerized tomography. *Spine* 2005;30:2084-8.
7. Dvorak M, MacDonald S, Gurr KR, et al. An anatomic, radiographic, and biomechanical assessment of extrapedicular screw fixation in the thoracic spine. *Spine* 1993;18:1689-94.
8. Yuksel KZ, Adams MS, Chamberlain RH, et al. Pullout resistance of thoracic extrapedicular screws used as a salvage procedure. *Spine J* 2007;7:286-91.
9. White KK, Oka R, Mahar AT, et al. Pullout strength of thoracic pedicle screw instrumentation: comparison of the transpedicular and extrapedicular techniques. *Spine* 2006;31:E355-8.
10. Husted DS, Yue JJ, Fairchild TA, et al. An extrapedicular approach to the placement of screws in the thoracic spine: an anatomic and radiographic assessment. *Spine* 2003;28:2324-30.
11. Lehman RA Jr, Lenke LG, Keeler KA, et al. Computed tomography evaluation of pedicle screw placed in the pediatric deformed spine over an 8-year period. *Spine* 2007;32:2679-84.

