



CLINICAL AND RADIOGRAPHIC OUTCOMES FOR THE TREATMENT OF SYMPTOMATIC DEGENERATIVE DISC DISEASE WITH THE SPINAL KINETICS M6®-L ARTIFICIAL LUMBAR DISC: RESULTS THROUGH 24 MONTH FOLLOW-UP IN A POST-MARKET SURVEILLANCE REGISTRY

As presented at the 13th Annual Meeting of the International Society for the Advancement of Spine Surgery, 3-5 April 2013, Vancouver, BC Canada

K. Ritter-Lang¹, N. Dreßler¹

¹ Semper Mobilitas Orthopädie und Wirbelsäulenchirurgie, Potsdam, Germany

Summary

- Ongoing prospective multi-site post market surveillance outside the United States. The 45 patients included in this analysis underwent disc replacement surgery and completed 24 month follow-up.
- By 24 months, mean back pain, as measured by the Visual Analog Score (VAS), had decreased by more than 61% compared to pre-operative scores. Right and left leg pain VAS also decreased significantly at each follow-up time point, and by 24 months, mean right and left leg pain VAS scores were 62% and 53% lower, respectively.
- At 24 months, functional disability, as measured by the Oswestry Disability Index (ODI), decreased by more than 54% compared to pre-operative results.
- No device or procedure related revisions at index or adjacent levels.
- Results from the M6-L Artificial Disc Study demonstrate satisfactory clinical and radiographic outcomes through 24 months.

CLINICAL AND RADIOGRAPHIC OUTCOMES FOR THE TREATMENT OF SYMPTOMATIC DEGENERATIVE DISC DISEASE WITH THE SPINAL KINETICS M6®-L ARTIFICIAL LUMBAR DISC: RESULTS THROUGH 24 MONTH FOLLOW-UP IN A POST-MARKET SURVEILLANCE REGISTRY

As presented at the 13th Annual Meeting of the International Society for the Advancement of Spine Surgery, 3-5 April 2013, Vancouver, BC Canada

M6^L
artificial lumbar disc



Introduction

The Spinal Kinetics M6®-L Artificial Lumbar Disc is a non-fusion motion preservation product designed to mimic the anatomic characteristics of a natural intervertebral disc. It aims to restore the physiological characteristics of an asymptomatic FSU without negatively affecting adjacent vertebral segments.

Materials & Methods

This is ongoing prospective, multi-site post market surveillance study outside the United States. After approbation by a local ethics committee, patients were required to sign an informed consent prior to enrollment in the study. Inclusion/exclusion criteria were based on the Instructions for Use (IFU) and Surgical Technique Manual of the M6-L device. The device is intended for use in patients undergoing surgery for treatment of DDD on the lumbar region of the spine at any one or two adjacent levels between L3 and S1. Patients enrolled were skeletally mature and nonresponsive to at least 6 months of non-operative conservative treatment. Patients must have also demonstrated signs and/or symptoms of disc herniation, osteophyte formation and/or loss of disc height.

Results

One hundred and one patients (50 males, 51 females) with mean age of 44 ± 14.1 and BMI 25.6 ± 4.6 underwent disc replacement surgery. To date 45 patients have completed full 24-month follow-up and are included in this analysis. Sixty-seven of the 101 patients enrolled in the study were treated at 1 level and 34 at multiple levels for a total of 138 implanted discs (Table 1).

Index Level(s)	N(% of Patients)
L4/L5	22 (22%)
L5/S1	45 (44%)
L3/L4 ; L4/L5	4 (4%)
L4/L5 ; L5/S1	27 (27%)
L3/L4 ; L4/L5 ; L5/S1	3 (3%)

Table 1: Patient Characteristics

Mean ODI was 45.1% at baseline and decreased significantly as early as 6 weeks and by 24 months, ODI was 20.8% (p<0.0001) (Figure 1).

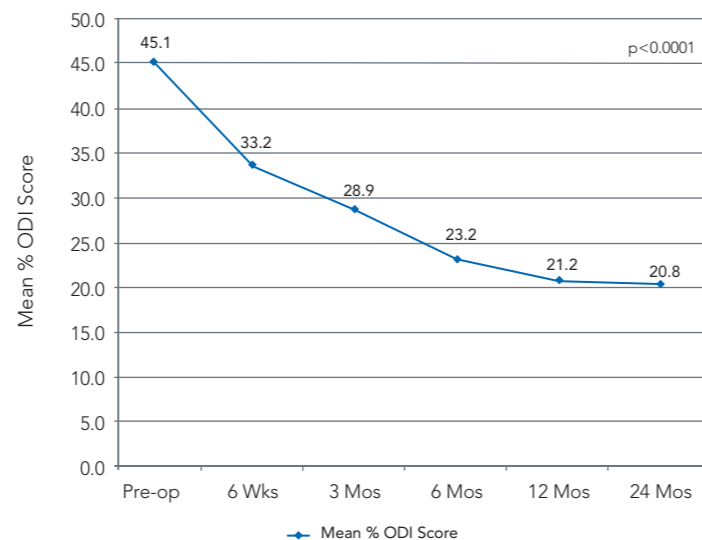


Figure 1: . Oswestry Disability Index

At 24 months, back pain, right and left leg pain VAS decreased significantly from baseline (p<0.001) (7.0, 3.5 and 4.0 at baseline versus 2.7, 1.3 and 1.9 at 24 months, respectively) (Figure 2).

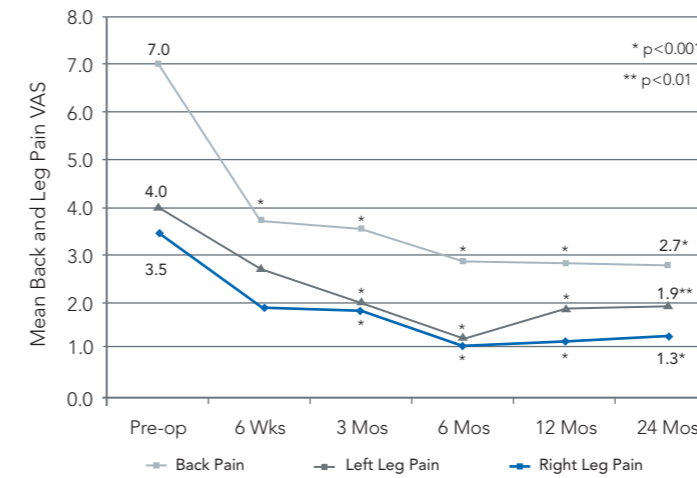



Figure 2: Pain VAS



M6-L Artificial Lumbar Disc Cross Section

Anterior and posterior disc height increased and remained stable through 24 months (Figure 3). As disc height was consistently restored, a significant increase in lordosis angle was also observed through the 2 year follow-up period. Global and index ROM have both been adequately maintained over time. There were no reported incidences of device- or procedure-related adverse events and no device removal, revision, or supplemental fixation at index or adjacent levels

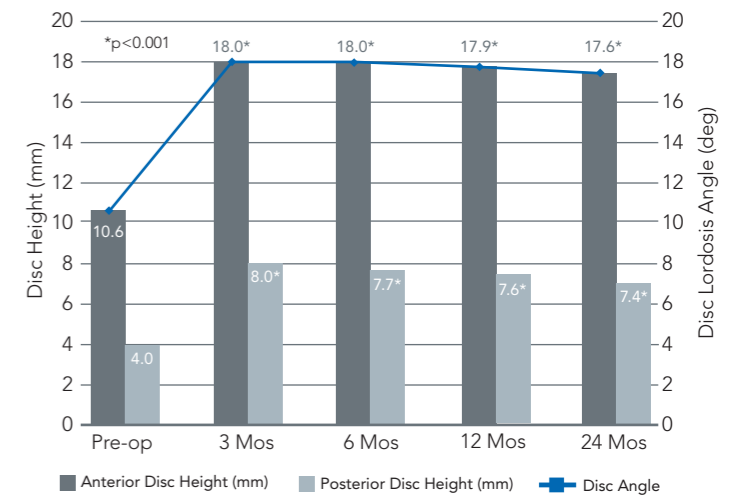


Figure 3: Anterior and Posterior Disc Space Height

Conclusions

Long-term follow-up results from the M6-L artificial lumbar disc post-market registry demonstrate significant improvement in clinical and radiographic outcomes through 24-month follow-up and support the safety and effectiveness of the device in treating symptomatic degenerative disc disease.