

Technical Note

New Technique for Cell-Seeded Collagen Matrix-Supported Autologous Chondrocyte Transplantation

Matthias Steinwachs, M.D.

Abstract: Autologous chondrocyte transplantation/implantation (ACT/ACI) is becoming increasingly common for the treatment of large cartilage defects in the knee joint. The traditional ACT technique involves injection of a suspension of cells into the cartilage defect, which is covered with a periosteal flap or collagen membrane. The technique requires extensive suturing to create an effective seal; however, cell leakage remains a potential problem. Matrix-induced autologous chondrocyte implantation (MACI/MACT) avoids this potential problem by using a membrane on which chondrocytes are seeded and cultured for several days, before the membrane is cut to the correct size and shape of the defect. Time-consuming extensive suturing is unnecessary. However, cutting and repeated manipulation of the seeded membrane may result in the loss of critical chondrocytes. A modified technique termed ACT-collagen membrane seeding (ACT-Cs) has been developed in which expanded chondrocytes are applied to the collagen membrane after it has been cut to size, substantially reducing the risk of viable cell loss while retaining the ease and speed of the MACI/MACT procedure. In addition, the seeding of mitotically active chondrocytes onto the membrane after expansion and immediately before transplantation allows direct application of high cell concentrations. **Key Words:** ACT—Cartilage repair—Chondrocyte—Collagen membrane—MACI—MACT.

Current surgical options for the treatment of knee cartilage defects include marrow stimulation techniques such as microfracture, autologous grafting procedures like osteochondral autologous transplantation system (OATS) and mosaicplasty, and, more recently, autologous chondrocyte transplantation (ACT, commonly referred to as autologous chondrocyte implantation [ACI]). Although widely used, marrow stimulation techniques produce predominantly fibro-

cartilaginous tissue that deteriorates over time,¹ and bony overgrowth may also occur.² Osteochondral grafts have been shown to provide repair tissue that is hyaline in character; however, a persistent interface between the transplant and surrounding cartilage was also observed.³ Consequently, use of ACT is becoming increasingly widespread, with multiple studies reporting good results in terms of defect filling, adherence to bone, integration with existing cartilage, and mechanical properties of the repair tissue, as well as for the long-term clinical outcome.^{4,5}

In traditional ACT,^{4,6} cells are harvested from a cartilage biopsy taken during initial arthroscopy and cultured in vitro to produce a concentrated cell suspension. During a second surgical procedure, the prepared defect is covered with a periosteal flap, beneath which a suspension of the cultured cells is injected. This traditional ACT procedure relies on good stability and sealing of the periosteal flap to minimize the

From the Center of Orthobiologics and Cartilage Repair, Schulthess Klinik, Zürich, Switzerland.

The author reports no conflict of interest.

Address correspondence and reprint requests to Matthias Steinwachs, M.D., Center of Orthobiologics and Cartilage Repair, Schulthess Klinik, Lengghalde 2, CH-8008, Zürich, Switzerland. E-mail: matthias.steinwachs@kws.ch

© 2009 by the Arthroscopy Association of North America

0749-8063/09/2502-8550\$36.00/0

doi:10.1016/j.arthro.2008.10.009

risk of cell leakage under the loading conditions of the joint. Consequently, excision of a periosteal flap that is slightly larger than the defect size is necessary to compensate for subsequent periosteum shrinkage. In addition, mesenchymal cells and growth factors present in the periosteum may contribute to the risk of later hypertrophy, which has been described in up to 26% of patients.⁴ Collagen membranes are increasingly used to avoid the additional morbidity associated with excision of a periosteal flap and to reduce the risk of later hypertrophy.^{1,7} However, both collagen membranes and periosteal flaps may require extensive suturing to achieve a water-tight seal, and cell leakage remains a potential problem. Furthermore, the sutures must be very stable to resist shear forces resulting from knee movement.

Recently, modifications to the ACT technique have been developed to address these issues. Matrix-induced autologous chondrocyte implantation (MACI; Genzyme, Cambridge, MA) follows a similar 2-step procedure to that of traditional ACT. However, instead of injecting a suspension of expanded cells into the defect, this technique uses a collagen type I/III membrane which is seeded with autologous chondrocytes harvested from the initial biopsy. The seeded membrane is then cultured for several days before implantation. During the second surgical procedure, a template of the defect is created and used to cut the seeded membrane to the correct size and shape. The cut membrane is then placed in the defect and secured with fibrin glue and, if necessary, minimal sutures. Because the chondrocytes adhere to the membrane, the risk of cell leakage is avoided and extensive, time-consuming suturing is unnecessary. The MACI/MACT technique is simpler and quicker than traditional ACT.

For all methods of cartilage regeneration through implantation of autologous chondrocytes, implantation of sufficient cells for good production of repair tissue is critical. Only good quality, highly mitotically active cells attach at the subchondral bone plate, by the synthesis of adhesion molecules. The creation of cell-cell contacts is the first step in tissue formation. In the second step, the high cellularity induces a switch in gene expression in response to the local environment and biomechanics, and the defects are filled completely with repair cartilage. Because the autologous cells are cultured on the membrane before cutting, potential limitations of the MACI/MACT technique are the use of lower, variable numbers of cells, which are attached to the biomaterial and not the

bottom of the defect, and loss of vital chondrocytes through repeated membrane manipulation during the implantation process. This technical note describes a modified technique termed ACT-collagen membrane seeding (ACT-Cs), which is designed to substantially reduce the risk of viable cell loss, allowing the application of high concentrations of mitotically active cells while retaining the ease and speed of the MACI/MACT procedure.

TECHNIQUE

Similar to other ACT procedures, ACT-Cs is performed over the course of 2 surgical procedures. The key steps are shown in Fig 1. Autologous chondrocytes are harvested through enzymatic digestion of a cartilage biopsy taken during initial arthroscopy as previously described.^{4,6} The harvested chondrocytes are expanded *in vitro* to produce a high-density cell suspension. During the second surgical step, the defect is prepared as for other ACT procedures, with debridement of cartilage to produce vertical edges surrounding the defect and filing of any uneven bone formation. Care should be taken to maintain an intact subchondral bone plate to prevent bleeding and contamination of the defect area by other cell types. Similar to MACI/MACT, a template of the prepared defect is created (using aluminum foil) and used to cut a collagen membrane to the exact defect size and shape. However, unlike MACI/MACT, the dry membrane is cut to size before chondrocyte seeding. In ACT-Cs, a bilayer membrane based on porcine collagen type I and III is used (Chondro-Gide; Geistlich Biomaterials, Wolhusen, Switzerland). This membrane has an external barrier surface with good mechanical strength and a porous inner surface layer that stimulates cells to produce cartilage-specific matrix molecules.⁸ Once cut to size, the dry membrane is marked to define the correct orientation and placed in a suitable sterile container. Special instruments (Karl Storz, Tuttlingen, Germany) can be used to cut both the cartilage and membrane (Fig 2).

The upper porous layer is then carefully seeded with the cultured chondrocytes, to a minimum density of 10^6 cells/cm². During a 10-minute incubation period at room temperature, the chondrocytes adhere to the porous layer and the seeded membrane can be transferred to the defect. The seeded porous layer, which stimulates metabolic activity in adhered cells, is placed on the bone surface, thereby facilitating cell adherence. The membrane is secured using fibrin glue with minimal suturing if necessary, depending on le-

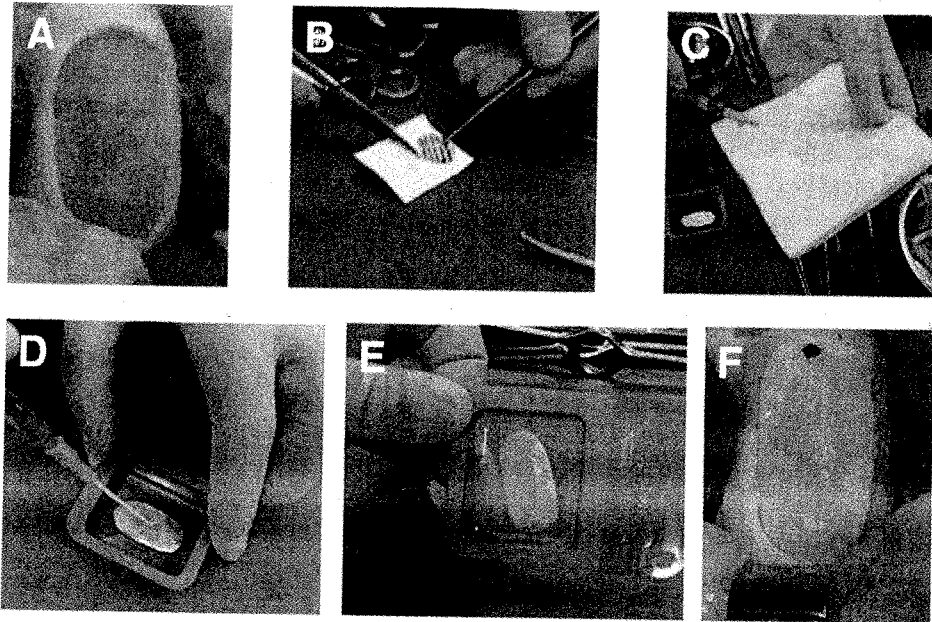


FIGURE 1. Key steps of autologous chondrocyte transplantation-collagen membrane seeding. The cartilage defect is prepared and a defect template created (A). The membrane is then cut to the correct size and shape based on the template (B). The water supernatant from the cell solution is released to obtain a high cell density (C). The porous side of the dry Chondro-Gide membrane (Geistlich Biomaterials, Wolhusen, Switzerland) is seeded with autologous chondrocytes (D). After 10 minutes of cultivation, the whole volume of the applied cell solution is absorbed (E). The seeded bilayer membrane is placed in the defect with porous side to the subchondral bone plate (F) and secured with fibrin glue or vertical sutures. Repair tissue is generated and the membrane degrades.

sion location and size, and whether the lesion is contained. If used, suturing is performed using the inside-out technique. During the recovery period, the implanted cells generate repair tissue, filling the defect from the bone front outwards, and the membrane is gradually degraded. After treatment, patients follow a similar rehabilitation program to those associated with other ACT techniques.

DISCUSSION

The development of ACT-Cs represents an important progression of the widely accepted ACT-based techniques. Seeding the collagen membrane after cutting to size minimizes the risk of cell loss through subsequent manipulations and allows for the application of cells at a higher density than can usually be

FIGURE 2. Key steps of autologous chondrocyte transplantation-collagen membrane seeding using specialized cutting instruments. The cartilage defect is prepared using a special cutting system (A-C; K Storz, Tuttlingen, Germany). The Chondro-Gide membrane (Geistlich Biomaterials, Wolhusen, Switzerland) is seeded with the cultivated cells using the same technique as described in Fig 1. The cell-loaded membrane (D) is cut using the same instrument as was used to prepare the defect. After 10 minutes of cultivation, the whole volume of the applied cell solution is absorbed (E). The seeded membrane is placed in the defect, with the cell-loaded porous side to the bone plate, and secured using fibrin glue (F) and/or sutures.

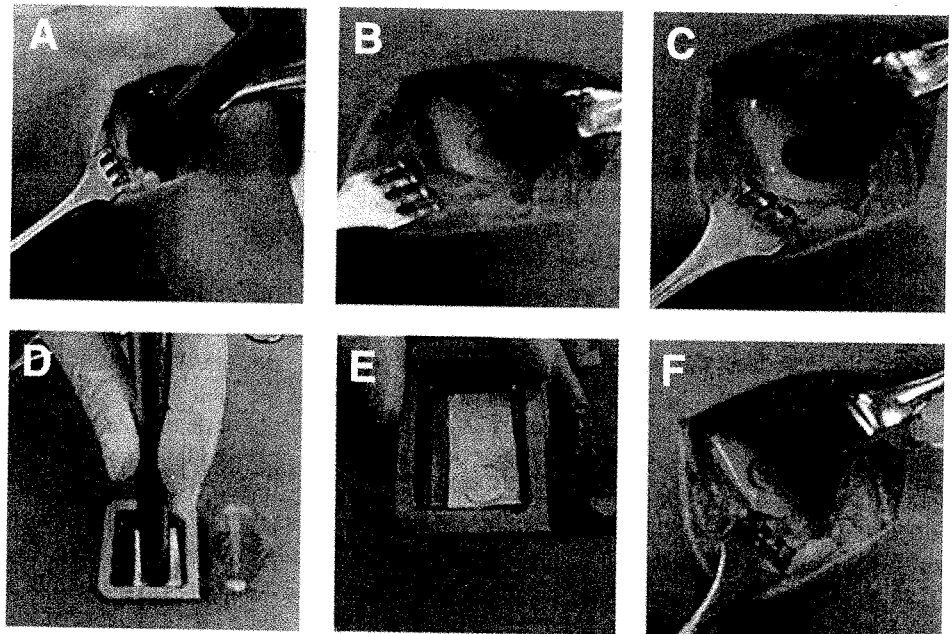
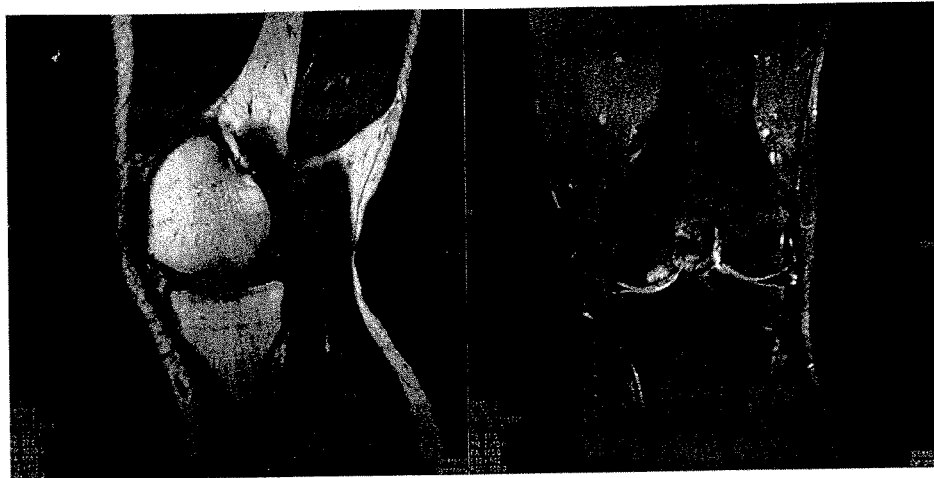

FIGURE 3. Magnetic resonance imaging results 6 months after autologous chondrocyte transplantation-collagen membrane seeding. Magnetic resonance imaging results indicate good integration and filling of the defect 6 months after the autologous chondrocyte transplantation-collagen membrane seeding procedure. Minimal edema is evident and normal at this time.



achieved through culturing in the matrix or on membranes for use with the MACI/MACT technique. Furthermore, careful application of the cell suspension to the membrane immediately before use ensures an even distribution of cells across the entire surface, whereas culturing the cells on a membrane for several days before surgery may result in a nonhomogeneous cell layer because of the lower cell density applied and possible cell loss through subsequent manipulations. The homogeneous, high-cell density layer achieved using ACT-Cs facilitates final cell expansion in vivo and shortens the time to subsequent matrix production, thereby reducing recovery and rehabilitation time. Importantly, the simplicity of the technique and minimal suturing required translate into a considerable reduction in operating time, comparable to that of MACI/MACT.

Preliminary results from the use of the collagen membrane have been encouraging, revealing significant improvement in magnetic resonance imaging, International Cartilage Repair Society and Cincinnati scores, and only minimal, asymptomatic hypertrophy (9.5% of patients).⁷ Magnetic resonance imaging results suggest good defect fill and integration into the surrounding cartilage with minimal subchondral bone changes 6 months postsurgery (Fig 3).

ACT-Cs builds on established and accepted techniques, providing improved cartilage regeneration capabilities through increased cell density and good cell attachment, while minimizing problems associated with existing procedures. Importantly, this technique is simple and quick, and therefore represents a promising development in the treatment of cartilage defects.

Acknowledgment: The author thanks Insight Medical Writing Ltd (Finstock, Oxfordshire, England) for their assistance in preparation of this manuscript.

REFERENCES

1. Vanlauwe J, Almqvist F, Bellemans J, Huskin JP, Verdonk R, Victor J. Repair of symptomatic cartilage lesions of the knee: The place of autologous chondrocyte implantation. *Acta Orthop Belg* 2007;73:145-158.
2. Brown WE, Potter HG, Marx RG, Wickiewicz TL, Warren RF. Magnetic resonance imaging appearance of cartilage repair in the knee. *Clin Orthop Relat Res* 2004;422:214-223.
3. Horas U, Pelinkovic D, Herr G, Aigner T, Schnettler R. Autologous chondrocyte implantation and osteochondral cylinder transplantation in cartilage repair of the knee joint: A prospective, comparative trial. *J Bone Joint Surg Am* 2003; 85:185-192.
4. Peterson L, Minas T, Brittberg M, Nilsson A, Sjögren-Jansson E, Lindahl A. Two- to 9-year outcome after autologous chondrocyte transplantation of the knee. *Clin Orthop Relat Res* 2000;374:212-234.
5. Saris DB, Vanlauwe J, Victor J, et al. Characterized chondrocyte implantation results in better structural repair when treating symptomatic cartilage defects of the knee in a randomized controlled trial versus microfracture. *Am J Sports Med* 2008; 36:235-246.
6. Brittberg M, Lindahl A, Nilsson A, Ohlsson C, Isaksson O, Peterson L. Treatment of deep cartilage defects in the knee with autologous chondrocyte transplantation. *N Engl J Med* 1994; 331:889-895.
7. Steinwachs M, Kreuz PC. Autologous chondrocyte implantation in chondral defects of the knee with a type I/III collagen membrane: A prospective study with a 3-year follow-up. *Arthroscopy* 2007;23:381-387.
8. Fuss M, Ehlers EM. Characteristics of human chondrocytes, osteoblasts and fibroblasts seeded onto a type I/III collagen sponge under different culture conditions. A light scanning and transmission electron microscopy study. *Ann Anat* 2000;182:303-310.