

## Clinical Outcomes of Patients Treated with Percutaneous Hydrodiscectomy for Radiculopathy Secondary to Lumbar Herniated Nucleus Pulposus

---

Mitchell A Hardenbrook M.D. The Boston Spine Group Newton, Massachusetts USA

David P. Gannon Jr. M.D. Cape Cod Pain Management Plymouth, Massachusetts USA

Emad Younan M.D. Pain Center Of The North Shore Peabody, Massachusetts USA

Michael L. Amoroso M.D. The Spine and Pain Center Oakhurst, New Jersey USA

Jose E. Rodriguez M.D. Orthopaedic Institute of Spinal Disorders Houston, Texas USA

Tomi T. Prvulovic M.D. Healthspine and Anesthesia Institute Goshen, New York USA

---

**Citation:** M.A. Hardenbrook , D.P. Gannon Jr. , E. Younan, M.L. Amoroso , J.E. Rodriguez , T.T. Prvulovic : Clinical Outcomes of Patients Treated with Percutaneous Hydrodiscectomy for Radiculopathy Secondary to Lumbar Herniated Nucleus Pulposus. *The Internet Journal of Spine Surgery*. 2013 Volume 7 Number 1. DOI:

---

**Keywords:** Percutaneous lumbar discectomy, percutaneous microdiscectomy, percutaneous mechanical disc decompression, lumbar herniated nucleous pulposus, radiculopathy

---

### Abstract

**Introduction:** Acute herniated nucleus pulposus (HNP) in the lumbar spine is a common source of back and leg pain. Conservative treatment includes activity modification, medications and epidural steroid injection. Most patients improve with conservative treatment. Patients that fail to improve are referred for surgical decompression. A new minimally invasive procedure, percutaneous hydrodiscectomy, mechanically cuts and removes disc material using a high-velocity, non-thermal saline fluid jet through a 3.8mm cannulated system. The procedure is performed under local anesthesia with sedation with minimal tissue trauma, blood loss or complication. The purpose of this study is to evaluate the clinical outcomes of percutaneous hydrodiscectomy in treating patients with radiculopathy secondary to lumbar HNP.

**Methods:** A multi-center retrospective review was conducted on consecutive patients with lumbar HNP confirmed by MRI, who failed to improve with conservative management and were to be referred for decompressive surgery, but underwent percutaneous lumbar hydrodiscectomy at one or two levels. Patients with free fragment herniation, central stenosis or bone impingement were excluded. **Results:** A total of 50 patients (60% male) with a mean age of 52.6 years underwent percutaneous hydrodiscectomy at six centers between August 2008 and May 2012 with no intra-operative complications. A total of 63 lumbar levels were treated; 37 single-level and 13 two-level. One patient reported mild pain over the incision that resolved. There was one level that could not be performed because of patient's anatomy. Mean length of follow-up was 20 weeks (range 1 week to 27 months). Improvement in back pain and radiculopathy occurred in 94% of patients. Three patients had recurrent herniated discs after successful treatment. **Conclusion:** Percutaneous hydrodiscectomy is a viable treatment option with minimal risk of complications for patients with radiculopathy secondary to subligamentous lumbar herniated nucleus pulposus and can be added to the non-surgical treatment algorithm in select patients. Future prospective studies are warranted to substantiate the long-term benefits.

---

### Introduction

Lumbar disc herniation, defined as protrusions of disc material that go outside the confines of the annular lining, is a common condition that affects the spine in young and middle-aged adults and is one of the leading causes of lower back pain and sciatica.<sup>1,2</sup> Back pain may occur due to disc protrusions that do not enter the spinal canal or compromise the nerve roots, however, radiculopathy occurs when extruded disc material contacts or exerts pressure on the thecal sac or lumbar nerve root(s), and is considered the more treatable condition<sup>2</sup>. Pain occurs due to a combination of nerve root ischemia and inflammation resulting from local pressure and neurochemical inflammatory factors present within the disc material<sup>2</sup>.

Initial management of lumbar disc herniation includes conservative treatment such as rest, physical therapy, pharmacotherapy, activity modification, and alternative medicine options. In most cases, radicular symptoms will resolve within six weeks but if symptoms persist, consideration can be given to more invasive treatment such as epidural steroid injections or nerve blocks. Patients that have failed six weeks of conservative management and have no relief from steroid injections and continue to have symptoms with demonstrable MRI disc pathology are candidates for surgical referral<sup>2</sup>.

In the United States, approximately 300,000 patients each year undergo surgery to relieve symptoms related to lumbar herniated discs<sup>3</sup>. Microdiscectomy is the surgical intervention of choice for herniations causing radicular symptoms not relieved with non-operative management<sup>4, 5</sup>. Surgery provides 85 to 95% of patients with good to excellent outcomes post-operatively in the short-term but recurrence rate of lumbar disc herniation after lumbar microdiscectomy has been reported to be as high as 26%<sup>6</sup>. Additionally, higher rates of recurrence of herniation and repeat operation are reported with large annulotomies during access to the disc space<sup>1, 6</sup>. Microdiscectomy, while highly successful in select patients, additional complications such as hematoma, infection, residual spinal instability, and epidural fibrosis have warranted the advancement of newer less invasive procedures.

Minimally invasive percutaneous procedures were developed to address contained disc herniations and involve the removal of the nucleus pulposus using a variety of chemical, thermal, and/or mechanical techniques. The common principle of percutaneous treatments is to reduce intradiscal pressure in the nucleus and thereby create space for the herniated fragment to retract inwards thus reducing pressure on the nerve root to reduce pain<sup>7</sup>. Percutaneous mechanical lumbar discectomy was first reported by Hijikata in 1975<sup>8</sup>. Since then, many various techniques have been developed such as percutaneous disc decompression (PDD)<sup>9</sup>, automated percutaneous lumbar discectomy (APLD)<sup>10</sup>, percutaneous laser disc decompression<sup>11</sup> intradiscal electrothermal therapy (IDET)<sup>12</sup>, and intervertebral disc nucleoplasty<sup>13</sup>.

The percutaneous SpineJet™ Hydrodiscectomy System (HydroCision Inc., N. Billerica, MA, USA) was developed as a less invasive alternative to traditional microdiscectomy. The procedure is performed under local anesthesia with sedation and uses an image-guided technique and 3.8mm cannulated system to dilate the annular fibers to access the disc space. Nuclear disc material is mechanically removed using a high-velocity, non-thermal saline fluidjet that pulverizes the disc tissue to internally decompress the disc with minimal disruption of surrounding tissues. This technique dilates the fibers of the annulus creating a small annulotomy that results in less potential annular defect for re-herniation to occur while minimizing the manipulation of the nerve root<sup>8, 14</sup>.

The purpose of this study is to evaluate the clinical outcomes of patients that had percutaneous hydrodiscectomy for treatment of radiculopathy secondary to lumbar herniated nucleus pulposus that have failed conservative treatment.

## **Materials and Methods**

### **Patient Population and Assessments**

This study is a retrospective multi-center study reviewed by New England Institutional Review Board (NEIRB #11-020). Retrospective chart review was conducted on consecutive patients that had percutaneous hydrodiscectomy performed by two orthopaedic spine surgeons and four interventional pain physicians at 6 centers between August 2008 and May 2012.

Patients that were included in the study had a diagnosis of confirmed subligamentous lumbar disc herniation by magnetic resonance imaging (MRI), documented unilateral radicular pain attributed to nerve root impingement from lumbar herniated disc material, and a minimum of 6 weeks of conservative treatment. The patients would be considered for surgical decompression but instead underwent percutaneous hydrodiscectomy.

Patients were excluded from the study for any of the following conditions: free fragment herniations, hydrodiscectomy at more than 2 levels, discogenic pain without nerve root compression, segmental instability, spondylolisthesis, severe central canal stenosis or bony impingement at the index level.

Basic demographics, diagnosis, location and nature of herniation(s), failed conservative treatments, spinal surgical history, neurological status, procedure information, adverse events and complications were recorded as available. Information recorded at post-operative follow-ups included patient status (Improved, No Improvement, or Worse), adverse events, complications, new treatment or surgery at the treated level, and MRI findings, if a post procedure MRI was required.

The primary endpoint for the study was clinical success defined as improvement in radicular symptoms. Short-term clinical success was defined as improvement in radicular symptoms within 6 months post procedure compared to baseline based on the criteria used by Parr and Manchikanti in their systematic reviews of lumbar epidural steroid injections<sup>15, 16</sup>.

Safety was defined as adverse events related to the procedure or device. Adverse events were evaluated at the time of the procedure and at all available patient follow-ups.

## Hydrodiscectomy Technique

Percutaneous hydrodiscectomy is performed using an approach similar to standard discography. The patient is placed in the prone position on a radiolucent table to visualize the disc under fluoroscopic guidance. Local anesthesia with conscious sedation is utilized to perform the procedure. The back was prepped in the usual fashion and a single dose of prophylactic antibiotics was administered.

A stab incision is made approximately 7cm off the mid-line on the side of the pathology utilizing standard fluoroscopic vertebral body anatomy. The access guide needle is positioned under live fluoroscopy on the surface of the annulus just lateral to the border of the superior articulating process at the treated level. The needle is advanced into the disc under intermittent live fluoroscopy until it is approximately in the center of the nucleus, midway between either endplate. Proper placement is confirmed with A/P and lateral fluoroscopic images. A guide wire is then threaded through the needle (Figures 1a and 1b).

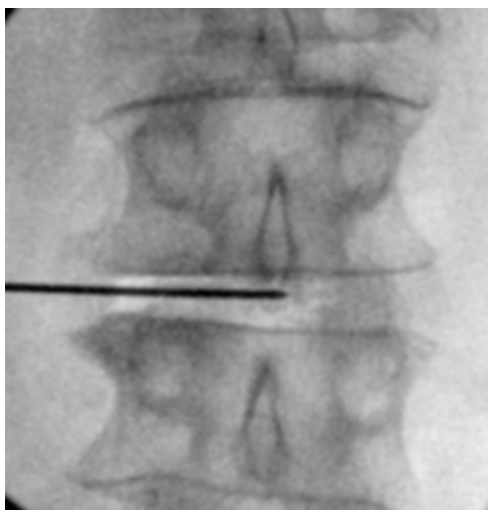


Figure 1a: Access needle and guide wire placement, A/P view.

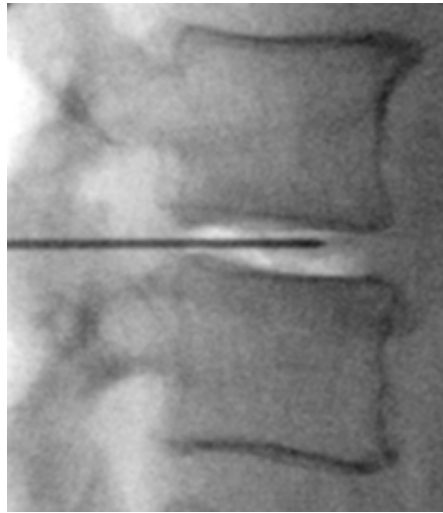


Figure 1b: Access needle and guide wire placement, lateral view.

The access guide needle is removed. Dilator and working cannula is inserted together over the needle through the annular fibers and advanced approximately one quarter of the distance into the nucleus (Figure 2). Proper position is confirmed fluoroscopically and the dilator and guide wire are removed leaving the working cannula in place.

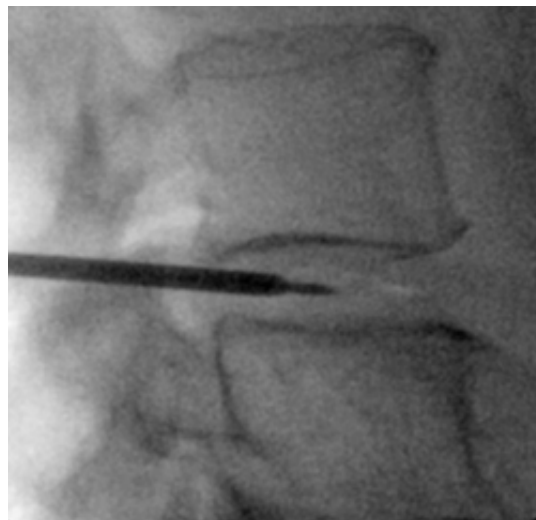


Figure 2: Dilator and working cannula advanced.

The SpineJet PercResector is inserted through the working cannula and activated using a pistoning, wandng and rotation motion keeping the tip in continual contact with the nucleus pulposus (Figure 3.) Cadaveric studies measuring disc consumption shows the PercResector pulverizes and removes disc material in a linear fashion<sup>14</sup> (Graph 1). In this study, the PercResector was activated for 3 minutes removing approximately 2 grams of nucleus pulposus. At the completion of the procedure, the PercResector and cannula is removed and a transforaminal epidural steroid is injected at the index level. The incision is closed with Dermabond or Steri-strips and a sterile bandage is placed to keep the incision

dry for 24 hours.

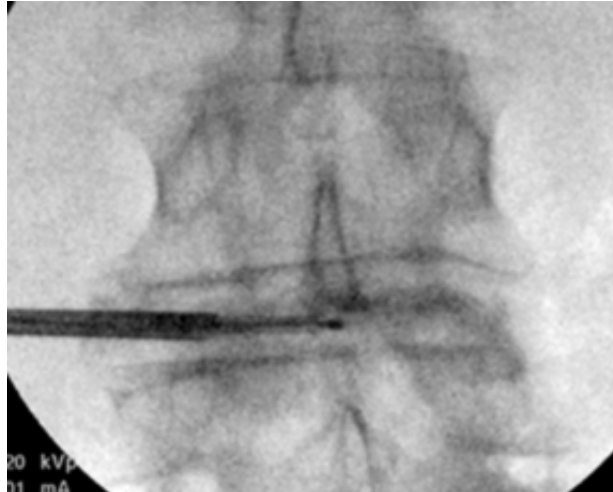


Figure 3a: PercResector inserted in the cannula, A/P view.

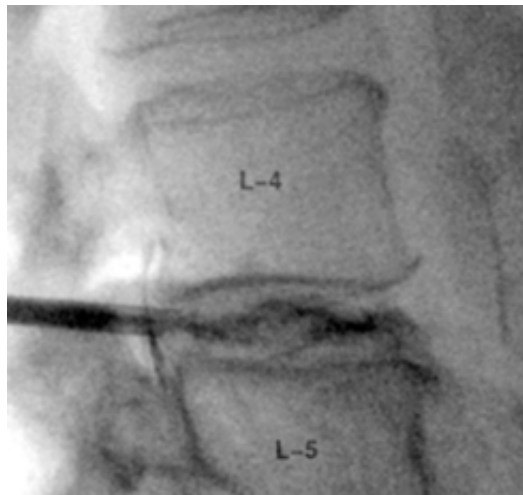
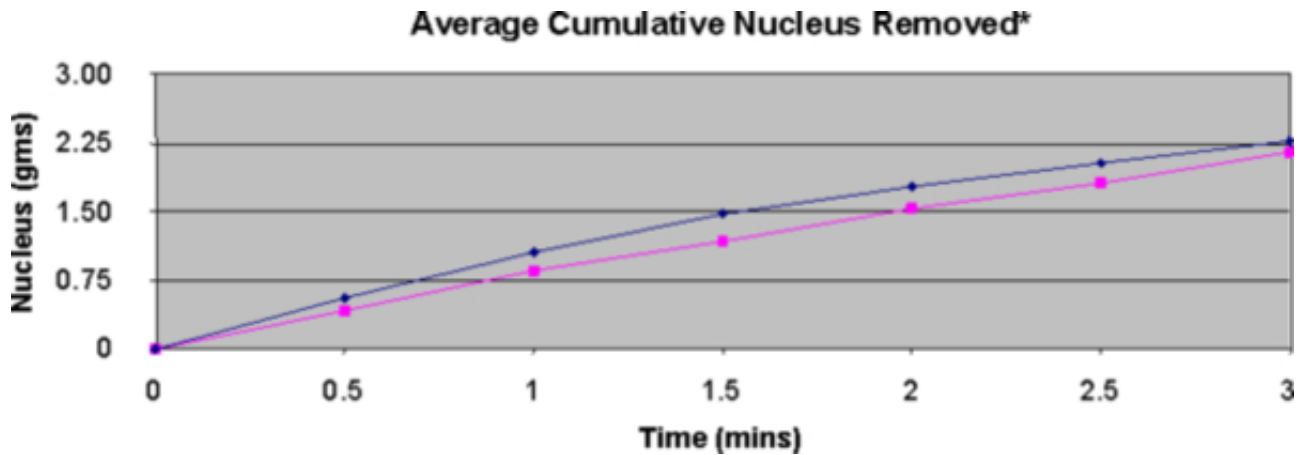


Figure 3b: PercResector inserted in the cannula, lateral view.



Graph 1. Linear excision of nucleus material in a cadaver model using PercResector on 69yo male (red) and 39yo female (blue.)<sup>14</sup>

## Results

Fifty patients (20 women and 30 men) with a mean age of 52.6 years (range 26-84 years) were included in the study. The average height and weight was 68.2 inches (range 60.5-76 inches) and 190.7 lbs (range 104-305 lbs), respectively. The median duration of symptoms prior to the hydrodiscectomy procedure was 12 months (range 2-132 months). Sixty-eight percent of the patients had no prior spinal surgical history, 29% had prior lumbar surgery and 2% had prior cervical/thoracic surgery. All patients had documented failed conservative treatment that included tranforaminal epidural steroid injections in 98% of the patients.

Percutaneous hydrodiscectomy was performed on a total of 63 lumbar herniated discs; 37 patients were treated at a single level and 13 patients were treated at two levels. Eighty-one percent of the procedures were performed at L4-L5 and L5-S1, 1 patient had 2 non-congruent levels treated (See Table 1). Sixty-five percent of the procedures were performed on the left side. One attempted L5-S1 was unsuccessful due to the patient's anatomy. No complications were reported. There was one report of mild pain over the hydrodiscectomy entry port post-operatively that resolved with anti-inflammatories. The mean length of follow was 20 weeks (range 1 week to 27 months).

Single Level	n=38	Two Level	n = 13
L3-L4	n = 4	L2-L3, L3-L4	n = 2
L4-L5	n = 20	L3-L4, L4-L5	n = 3
L5-S1	n = 13	L4-L5, L5-S1	n = 7
		L2-L3, L4-L5	n = 1

Table 1. Hydrodiscectomy Levels

Forty-seven patients (94%) of the 50 patients improved following the hydrodiscectomy procedure and met the criteria for short-term clinical success. Three patients (6%) did not experience an improvement in symptoms. No patients reported worse symptoms. Of the three patients with no improvement, 2 were referred for surgical decompression and one was lost to follow-up; individual patient outcomes are

presented in Table 2.

<b>Patient</b>	<b>Level</b>	<b>Surgical History</b>	<b>Outcome</b>
Male, 32yr	L5-S1	None	No improvement in symptoms, no further follow-up after 3 months
Male, 43yr	L4-5, L5-S1	None	No improvement in symptoms, microdiscectomy after 3 months
Female, 69yr	L4-5	None	Very short-term relief (2 week), referred for surgical options, no further follow-up

Table 2. Patients with no improvement after Hydrodiscectomy

There were seven patients (14%) with initial improvement after the procedure that had a recurrence of symptoms. Three of the seven patients had recurrent herniated discs at the same level documented by MRI with gadolium requiring surgical decompression. The remaining 4 patients had gradual return of symptoms an average of 1 year after the procedure. One patient was treated with surgical decompression, one patient was treated with medication and two patients were referred for spinal cord stimulator implant (Table 3.) Three of the patients in this group were 73 to 81 years old.

<b>Patient</b>	<b>Level</b>	<b>Surgical History</b>	<b>Outcome</b>
Male, 36yr	L5-S1	Recurrent HNP	Sudden onset pain, recurrent HNP and microdiscectomy at 15 months
Male, 34yr	L4-5	None	Tugged on lawnmower, recurrent HNP, microdiscectomy at 4 months
Male, 41yr	L4-5, L5-S1	None	Recurrent HNP during work hardening program, microdiscectomy at 6 months Patient on Coumadin and morbidly obese
Male, 40yr	L5-S1	None	Referred for surgery but opted for repeat hydrodiscectomy with no improvement, surgical decompression at 12 months for progressively increasing foraminal stenosis
Male, 73yr	L4-5, L5-S1	None	Pain returned 11 month post-procedure, not a surgical candidate, prescribed pain medication
Male, 80yr	L2-3, L3-4	None	Hydrodiscectomy repeated at 11 months, recommend spinal cord stimulation
Male, 81yr	L4-5, L5-S1	Laminectomy L4-5	Diagnosed failed back syndrome at 1 year, put on spinal cord stimulator trial

Table 3. Patients with recurrence of symptoms after successful treatment

A total of six patients were referred for surgical decompression after undergoing percutaneous hydrodiscectomy (12%). Three were the result of recurrent herniated nucleus pulposus 4 to 15 months status post the hydrodiscectomy procedure (Table 3.) Two patients were referred because of failure to improve with hydrodiscectomy (Table 2.) One patient had worsening symptoms secondary to foraminal stenosis 12 months after the index procedure and underwent surgical decompression (Table 3.)

## Discussion

Lumbar discectomy is the standard of care for surgical treatment for radicular pain secondary to herniated nucleus pulposus. The success rates in the treatment of sciatic pain reported over the last 30 years range from 49-98% depending on the length of follow-up, patient selection, and definition of success<sup>17, 18, 19, 20</sup>. While highly successful, the complication rate of lumbar discectomy has been reported to range from

2-14%<sup>21</sup>. The procedure, originally described by Mixter and Barr in 1934 involved a lengthy midline incision, extensive muscle retraction with full laminectomy before disc removal was achieved<sup>22</sup>. Since then, the procedure has undergone continued refinement to limit complications and improve patient outcomes.

In 1964, chemonucleolysis was introduced by Smith as an alternative to surgery for the treatment of sciatica and mechanical back conditions<sup>23</sup>. Percutaneous chemonucleolysis acts through the biochemical degradation of the nucleus pulposus and was widely used until studies showed that chymopapain injections have less successful outcomes than open discectomy procedures<sup>24, 25, 26</sup>. Additionally, the use of chymopapain in the US was discontinued due to a risk of anaphylactic reactions.

Percutaneous mechanical nucleotomy techniques were first reported by Hijikata in 1975 to allow for dilation of annular fibers rather than cutting through the annulus and offered some protection of the nerve root through the use of a cannulated system using the same approach to the disc space as applied to discography<sup>8</sup>. Although successful results were initially reported (72% success in 136 patients), limitations to disc removal due to the small diameter of the working cannula restricted its use. In 1983, refinements to the posterolateral cannulated instrumentation by Kambin for percutaneous nucleotomy partially eliminated these problems however, the dorsal part of the intervertebral disc could not be accessed<sup>27, 28</sup>. In 1985, Onik<sup>29</sup> introduced automated percutaneous lumbar discectomy (APLD) that involved a percutaneous posterolateral portal to the disc nucleus with pneumatically driven suction cutting probe for removal of disc material. Early reports demonstrated some efficacy with these techniques but without visualization of the disc space, when compared to open methods, results were inferior<sup>30, 31, 32</sup>.

Despite the limitation of these techniques, utilization of percutaneous mechanical decompression techniques have continued to increase over the years and extensive experience has been reported. At the time of the writing of a review article by Onik and Helms in 1990, they reported that more than 3,000 physicians had been trained on the procedure and over 40,000 cases performed worldwide<sup>29</sup>. In a recent systematic review to evaluate the current evidence of APLD, Hirsch et al, concluded there is enough evidence that APLD provides relief in properly selected patients with contained lumbar disc prolapse with studies demonstrating approximately 75% success rate with minimal risk<sup>10</sup>. Further, they concluded that APLD is considered safer than microdiscectomy since it utilizes the Nucleotome probe that reduces the number of times needed to enter the disc space to remove nucleus pulposus.

A modified version of APLD, the Dekompressor system (Stryker, Kalamazoo, MI, USA) removes a predetermined amount of disc material using a high rotation per minute cutting device. A randomized study compared percutaneous Dekompressor microdiscectomy to lumbar epidural steroid injection for treatment of radicular pain associated with contained lumbar disc herniation and at 6 weeks post-operatively concluded that Dekompressor is a more effective treatment for radicular pain of discogenic origin than epidural injections with steroid/local anesthetic<sup>33</sup>. Alo reported a 74% and 65% reduction in pain relief at 6 and 12 months respectively<sup>34</sup>.

Percutaneous laser disc decompression (PLDD) uses laser energy to reduce intradiscal pressure by vaporizing a small volume of nucleus pulposus, reducing the pressure between the peri-discal tissue and the nucleus pulposus causing retraction of the herniation away from the nerve root. The most frequently described complication of PLDD is spondylodiscitis with a frequency reported up to 1.2%<sup>11</sup>. Aseptic discitis results from heat damage to the disc or adjacent vertebral endplates. An 8% rate of thermal nerve root damage was reported in PLDD using a CO<sub>2</sub> laser through a metal cannula<sup>11</sup>. Reported clinical success rates range from 56-87% with an average of 72%<sup>11</sup>.

The percutaneous Hydrodiscectomy System used in this study is a cannulated system (3.2mm resector inside a 3.8mm diameter cannula) that uses a high-velocity saline fluid-jet to simultaneously cut, ablate and remove targeted nuclear soft tissue to decompress the nerve root with minimal injury to the annulus or vertebral endplates. In the current study, 94% of patients had improvement of their back and radicular symptoms after treatment with percutaneous Hydrodiscectomy. This compares favorably with clinical results from both surgical decompression<sup>17, 18, 19, 20</sup> as well as other previously published results from percutaneous treatment of lumbar radiculopathy<sup>10, 11, 33, 34</sup>. Seven patients in this study (14%) had



recurrence of symptoms after successful treatment. However, three of the seven patients had a new herniation causing their symptoms; two while performing high-intensity activities (one while pulling on jammed lawn-mower and one while exercising during work-hardening program.) Additionally, three of the seven patients with recurrence of symptoms were 73 to 81 years old. As this patient population often has some degree of instability, bony impingement and stenosis, they are not ideal candidates for percutaneous Hydrodiscectomy.

The cannulated system dilates the annular fibers rather than cutting them thereby minimizing the size of the residual annulotomy. This may potentially reduce the risk of re-herniation and minimizes the surface area available for formation of scar tissue/fibrosis while preserving future treatment options, including surgery. A study of 34 patients that compared traditional microdiscectomy to microdiscectomy performed using a 4mm diameter cannulated fluidjet system showed a statistically significant difference in the rate of leg pain and recurrent herniation at short-term follow-up<sup>33</sup>. In our study, 3 (6%) patients had reported cases of recurrent herniation.

No cases of infection or discitis were reported. There were no intra-operative complications, post-operative weakness or numbness. Because the system uses non-thermal energy, the risk of thermal damage to intradiscal or nervous structures is eliminated. One patient reported pain over the incision at the first post-procedure follow-up visit that resolved with medication over time.

Limitations of the patient's anatomy can result in the inability to access the disc space percutaneously, particularly at the L5-S1. Often times, this occurs when the patient has a high iliac crest, significant disc space collapse, significant facet arthrosis or a combination of the above. In this series, there was one patient who was to have percutaneous Hydrodiscectomy at L4-5 and L5-S1 where the L5-S1 level was unsuccessful due to patient anatomy. The patient had some improvement of symptoms with no negative sequella.

Carragee et al, studied the relationship between annular competence, presence of nuclear fragments, and clinical outcome following discectomy and concluded that the type of disc herniation had a significant relationship with clinical outcomes<sup>6</sup>. Their findings demonstrated worse clinical outcome from traditional discectomy in treating contained disc prolapses without annular defects; 38% had recurrent or persistent sciatica and statically significantly less improved outcome scores compared to the other herniation types. This group also required extensive anulotomy for removal of the protruding disc. Further experimental work has shown that the size of the annulotomy required for access to the nucleus in traditional discectomy is associated with annular incompetence and recurrence<sup>35</sup>. These findings suggest this patient population may benefit from newer techniques such as percutaneous Hydrodiscectomy that minimize injury to the annulus and warrant future research.

Percutaneous lumbar procedures have been successfully performed over the years and these results support currently accepted precutaneous procedures. Hydrodiscectomy is safe to perform in the hands of physicians who are experienced in standard discography and fluoroscopy techniques Although the limitations of this study include retrospective chart review and limited follow-up, the results support percutaneous hydrodiscectomy as a viable option with minimal risk and can be added to the non-surgical treatment algorithm in select patients before referring for surgical decompression.

## Conclusion

These preliminary results demonstrate that percutaneous hydrodiscectomy is a viable treatment option with minimal risk of complications for patients with radiculopathy secondary to subligamentous lumbar herniated nucleus pulposus. Short-term clinical success was 94%. Percutaneous hydrodiscectomy should be considered a treatment option between unsuccessful conservative therapy and surgical intervention. Future prospective studies are needed to substantiate the long-term benefits.

## References

1. Carragee E, Spinnickie A, Alamin T, Paragioudakis S: A prospective controlled study of limited versus subtotal posterior discectomy: short-term outcomes in patients with herniated lumbar intervertebral discs

- and large posterior annular defect. *Spine*; 2006; 31:653-657.
2. Schoenfeld AJ, Weiner BK: Treatment of lumbar disc herniation. Evidence-based practice. *International J of Gen Medicine*; 2010; 3:209-214.
  3. Slotman GJ, Stein SC: Laminectomy compared with laparoscopic discectomy and outpatient laparoscopic discectomy for herniated L5-S1 intervertebral disks. *J Laparoendosc Adv Surg Tech A*; 1998; 8:261-267.
  4. Kostuik J, Harrington I, Alexander D, Rand, et al: Cauda equina syndrome and lumbar disc herniation. *Journal of Bone and Joint Surgery*; 1986; 68-A:386-391.
  5. Awad J, Moskovich R: Lumbar disc herniations, surgical versus nonsurgical treatment. *Clinical Orthopaedics and Related Research*; 2006; 443:183-197.
  6. Carragee E, Han M, Suen P, et al: Clinical outcomes after lumbar discectomy for sciatica: the effects of fragment type and annular competence. *Journal of Bone and Joint Surgery*; 2003; 85-A:102-108.
  7. Kelekis AD, Filippiadis DK, Martin J-B, et al: Quality assurance guidelines for percutaneous treatments of intervertebral discs. Available at [www.cirse.org](http://www.cirse.org).
  8. Hijikata S, Yamagishi M, Nakayama T, Oomori K: Percutaneous nucleotomy: a new treatment method for lumbar disk herniation. *J Toden Hosp*; 1975; 5:5-13.
  9. Erginousakis D, Filippiadis DK, Malagari A, et al: Comparative prospective randomized study comparing conservative treatment and percutaneous disk decompression for treatment of intervertebral disk herniation. *Radiology*; 2011; 260(2):487-493.
  10. Hirsch JA, Singh V, Falco FEF, et al: Automated percutaneous lumbar discectomy for the contained herniated lumbar disc: a systematic assessment of evidence. *Pain Phys J*; 2009; 12:601-620.
  11. Singh V, Manchikanti L, Benyamin RM, et al: Percutaneous lumbar laser disc decompression: a systematic review of current evidence. *Pain Phys J*; 2009; 12:573-588.
  12. Helm S, Deer TR, Manchikanti L, et al: Effectiveness of thermal annular procedures in treating discogenic low back pain. *Pain Phys J*; 2012; 15:E279-E304.
  13. Manchikanti L, Derby R, Benyamin RM, et al: A Systematic Review of Mechanical Lumbar Disc Decompression with Nucleoplasty. *Pain Phys J*; 2009; 12:561-572.
  14. Hardenbrook MA, White S, Sukovich W: Hydrodiscectomy: a novel approach to lumbar microdiscectomy. AANS/CNS section on the disorders of the spine and peripheral nerves proceedings; 2007.
  15. Parr A, et al: Lumbar interlaminar epidural injections in managing chronic low back and lower pain extremity pain: A systematic review. *Pain Physician*; 2009; 12:163-188.
  16. Manchikanti L, Buenaventura RM, Manchikanti KM, et al: Effectiveness of therapeutic lumbar transforaminal epidural steroid injections in managing lumbar spinal pain. *Pain Physician*; 2012; 15:E199-E245.
  17. Javedan S, Sonntag VK: Lumbar disc herniation: microsurgical approach. *Neurosurgery*; 2003; 52(1):160-162.
  18. Sun EC, Wang JC, Endow K, Delamarter R: Adjacent two-level lumbar discectomy: outcome and SF-36 functional assessment. *Spine*; 2004; 29:E22-27.
  19. Wenger M, Mariani, Kalbarczyk A, Groger U: Long term outcome of 104 patients after lumbar sequestrectomy according to Williams. *Neurosurgery*; 2001; 19(2):329-331.
  20. Williams RW: Lumbar disc disease. Microdiscectomy. *Neurosurg Clin N Am* 4(1):101-108, 1993.
  21. Kim SH, Kim SC, Cho KH: Clinical outcomes of percutaneous plasma disc coagulation therapy for lumbar herniated disc diseases. *J Korean Neurosurg Soc*; 2012; 51:8-13.
  22. Mixter W, Barr J: Rupture of the intervertebral disc with involvement of the spinal canal. *N Engl J Med*; 1934; 211:210-15.
  23. Smith L, Garvin PJ, Gesler RM, et al: Enzyme dissolution of nucleus pulposus. *Nature*; 1963; 198:1311-1312.
  24. Nordby EJ, Fraser RD, Javid MJ: Chemonucleolysis. *Spine*; 1996; 21(9):1102-1105.
  25. Sutton JC: Chemonucleolysis in the management of lumbar disc disease: a minimum six year follow-up evaluation. *Clin Orthop Relat Res*; 1986; 206:46-60.
  26. Wittenberg RH, Oppel S, Rubenthaler FA, et al: Five year results from chemonucleolysis with chymopapain or collagenase: a prospective randomized study. *Spine*; 2001; 26(17):1835-1841.

27. Kambin P, Gellman H: Percutaneouslateral discectomy of the lumbar spine: a preliminary report. Clin Orthop; 1983; 174:127-132.
28. Kambin P, Brager MD: Percutaneous posterolateral discectomy. Anatomy and mechanism. Clin Orthop Relat Res; 1987: Oct;(223):145-54.
29. Onik G, Helms CA: Automated percutaneous lumbar discectomy. AJR Am J Roentgenol; 1991; 156:531-538.
30. Kotilainen E: Microinvasive lumbar disc surgery. A study on patients treated with microdiscectomy or percutaneous nucleotomy for disc herniation. Ann Chir Gynaecol; 1994; 209: 1-50.
31. Mochida J, Toh E, Nomura T, et al: The risks and benefits of percutaneous nucleotomy for lumbar disc herniation. A 10 year longitudinal study. J Bone Joint Surg Br; 2001; 83(4): 501-501.
32. Sahlstrand T, Lonntoft M: A prospective study of preoperative and postoperative sequential magnetic resonance imaging and early clinical outcome in automated percutaneous discectomy. J Spinal Discord Tech; 1999; 12(5):368-374.
33. Aronsohn J, Chapman K, Soliman M, et al: Percutaneous microdiscectomy versus epidural injection for management of chronic spinal pain. Proc West Pharmacol Soc; 2010; 53:16-9.
34. Singh V, Benyamin RM, Datta S, et al: Systematic Review of Percutaneous Lumbar Mechanical Disc Decompression Utilizing Dekompressor®. Pain Phys J; 2009; 12:589-599.
35. Ethier DB, Cain JE, Yaszemski MJ, et al: The influence of anulotomy selection on disc competence. A radiographic, biomechanical, and histologic analysis. Spine; 1994; 19:2071-6.

---

Generated at: Tue, 08 Jan 2013 08:26:21 -0600 (00002cea) — <http://www.ispub.com:80/journal/the-internet-journal-of-spine-surgery/volume-7-number-1/clinical-outcomes-of-patients-treated-with-percutaneous-hydrodiscectomy-for-radiculopathy-secondary-to-lumbar-herniated-nucleus-pulposus.html>

---